

# Stroke



Nina A Hilken, Barbara Casolla, Thomas W Leung, Frank-Erik de Leeuw

Stroke affects up to one in five people during their lifetime in some high-income countries, and up to almost one in two in low-income countries. Globally, it is the second leading cause of death. Clinically, the disease is characterised by sudden neurological deficits. Vascular aetiologies contribute to the most common causes of ischaemic stroke, including large artery disease, cardioembolism, and small vessel disease. Small vessel disease is also the most frequent cause of intracerebral haemorrhage, followed by macrovascular causes. For acute ischaemic stroke, multimodal CT or MRI reveal infarct core, ischaemic penumbra, and site of vascular occlusion. For intracerebral haemorrhage, neuroimaging identifies early radiological markers of haematoma expansion and probable underlying cause. For intravenous thrombolysis in ischaemic stroke, tenecteplase is now a safe and effective alternative to alteplase. In patients with strokes caused by large vessel occlusion, the indications for endovascular thrombectomy have been extended to include larger core infarcts and basilar artery occlusion, and the treatment time window has increased to up to 24 h from stroke onset. Regarding intracerebral haemorrhage, prompt delivery of bundled care consisting of immediate anticoagulation reversal, simultaneous blood pressure lowering, and prespecified stroke unit protocols can improve clinical outcomes. Guided by underlying stroke mechanisms, secondary prevention encompasses pharmacological, vascular, or endovascular interventions and lifestyle modifications.

## Introduction

Stroke is an acute, focal neurological deficit with no other explanation than a cerebrovascular cause. Common symptoms include hemiparesis, dysarthria, sensory deficits, aphasia, and visual deficits. Globally, with only little variation, ischaemic strokes constitute between 60–70% of all strokes and result from an acute arterial occlusion. Historically, transient ischaemic attack (TIA) was diagnosed when complete resolution of symptoms happened within 24 h, although nowadays the presence of a restricted diffusion lesion on MRI despite clinical recovery qualifies for a diagnosis of ischaemic stroke (irrespective of the duration of symptoms).<sup>1</sup> This qualification implies that a TIA is in fact a minor ischaemic stroke, which is also in line with advances in neuroimaging (eg, higher field strength) showing tissue loss in areas with only transient interruption of cerebral blood flow.<sup>2,3</sup> It is therefore doubtful if the term TIA is tenable—in fact it could distract from the immediate medical attention it deserves.

Lesions observable on diffusion-weighted imaging (DWI) can appear minutes after symptom onset and disappear within weeks contingent upon symptom duration and infarction volume.<sup>4</sup> However, without imaging confirmation of ischaemia, transient focal neurological episodes, hypoglycaemia, a postictal state, metabolic disturbances, or migraine with aura are potential stroke mimics. Postictal state, metabolic disturbances, or migraine with aura can also lead to DWI-positive lesions, mimicking acute ischaemic stroke.<sup>5</sup> Occasionally, functional disorders might also present with focal neurological deficits. Therefore, history taking, neurological examination, and relevant investigations are crucial steps to reach the definitive diagnosis. As the pathogenesis and secondary prevention mechanisms of TIA overlap with those of ischaemic strokes, TIA will

not be discussed separately in this Seminar. Cerebral venous thrombosis that constitutes less than 2% of all ischaemic strokes is beyond the scope of this Seminar given its distinct pathophysiology and treatment.

Intracerebral haemorrhages are due to acute vessel rupture, most often within the brain parenchyma. Globally there are marked differences in distribution of stroke subtypes. In high income countries (HICs) 15% of all strokes are intracerebral haemorrhages, whereas in low-income and middle-income countries (LMICs) intracerebral haemorrhage accounts for almost 30% of all

Published Online  
May 14, 2024  
[https://doi.org/10.1016/S0140-6736\(24\)00642-1](https://doi.org/10.1016/S0140-6736(24)00642-1)  
Department of Neurology, Radboud University Nijmegen Medical Center, Nijmegen, Netherlands (N A Hilken MD, Prof F-E de Leeuw MD); Donders Institute for Brain, Cognition and Behaviour, Radboud University, Nijmegen, Netherlands (N A Hilken, Prof F-E de Leeuw); Université Nice Côte d'Azur UR2CA-URRIS, Stroke Unit, CHU Pasteur 2, Nice, France (B Casolla MD); Division of Neurology, Department of Medicine and Therapeutics, The Prince of Wales Hospital, The Chinese University of Hong Kong, Shatin, Hong Kong Special Administrative Region, China (Prof T W Leung MD)

Correspondence to:  
Prof Frank-Erik de Leeuw, Department of Neurology, Radboud University Nijmegen Medical Center, PO Box 9101, Nijmegen 6500 HB, Netherlands  
[FrankErik.deLeeuw@radboudumc.nl](mailto:FrankErik.deLeeuw@radboudumc.nl)

## Search strategy and selection criteria

We searched the Cochrane Library, MEDLINE, and Embase for articles published in English between Jan 1, 2019, and Jan 31, 2024. When relevant we included older publications and papers that we deemed relevant from reference lists of papers identified. Review articles are cited to provide readers with more details and references. For the sections on acute treatment and secondary prevention we performed a systematic search by using the following search terms: “acute stroke treatment”, “ischaemic stroke”, “intravenous thrombolysis”, “endovascular thrombectomy”, “secondary prevention”, “antiplatelet therapy”, and “clinical trial” or “meta-analysis”. For the section on intracerebral haemorrhage, we used the following search terms: “brain haemorrhage”, “brain hemorrhage”, “cerebral haemorrhage”, “cerebral hemorrhage”, “intracerebral haemorrhage”, “intracerebral hemorrhage”, “brain bleeding”, “cerebral bleeding”, “intracerebral bleeding”, “cerebral haematoma”, “brain haematoma”, “intracerebral haematoma”, “ICH”, and “clinical trial” or “meta-analysis”. For the other sections, we selected studies with a substantial sample size (>100 people) that were published in high-impact, peer reviewed journals to provide the most recent and relevant advances.

strokes. Less frequently, acute arterial rupture can also occur in the subarachnoid space, resulting in a subarachnoid haemorrhage. Both subarachnoid and pure intraventricular haemorrhages are beyond the scope of this Seminar, and subarachnoid haemorrhage has also

been discussed in previous research.<sup>6</sup> This Seminar covers the diagnosis, acute management, and secondary prevention of ischaemic stroke and intracerebral haemorrhage, with a focus on recent developments and future perspectives.

Clinical		Diagnostic
<b>Ischaemic stroke</b>		
Arteriopathy		
Large artery disease or atherosclerosis	History of cardiovascular disease; presence of traditional vascular risk factors; often older than 50 years	Duplex, CT, or magnetic resonance angiography: stenosis of large vessels (cervical, intracranial) at typical sites
Cervical artery dissection	Often younger (18–50 years); cervical pain and headache; head trauma, cervical trauma, or both (often minor); tinnitus; Horner syndrome and cranial nerve palsy	CT or magnetic resonance angiography: long, irregular stenosis (so-called mouse tail appearance; starting >2 cm above the bifurcation for carotid cervical artery dissection); occlusion or a dissecting aneurysm, intramural hematoma; less often a double lumen or intimal flap
Sporadic small vessel disease		
Deep perforating vasculopathy	Traditional vascular risk factors (eg, hypertension); preceding cognitive decline	Recent subcortical infarction; MRI markers of small vessel disease
Cardioembolism		
Atrial fibrillation	Often older than 60 years; history of palpitations; multifocal neurological symptoms	ECG: atrial fibrillation; CT or MRI: multiple infarctions in different arterial territories
Infective endocarditis	Fever (fluctuating); cardiac murmur at auscultation; splinter haemorrhage; spondylodiscitis	Echocardiography: abscess, dehiscence of prosthetic valve; valvular regurgitation; valve vegetation
Other causes		
Vasculitis	Headache; behavioural and cognitive symptoms; other organ involvement (lungs, skin, joints, kidney, eye)	Raised erythrocyte sedimentation rate, C-reactive protein, or both; cerebrospinal fluid: mild pleocytosis, usually with protein elevation; contrast enhanced CT or MRI: multiple infarctions, at various stages, usually affecting different vascular territories, meningeal enhancement; intracerebral haemorrhage might be present; CT or magnetic resonance angiography: focal or multifocal segmental narrowing of branches of cerebral (or extracranial) arteries or occlusions with or without vessel wall enhancement
Antiphospholipid syndrome	History of arterial or venous thrombosis; history of pregnancy complications*	Positive antiphospholipid antibodies† at two different time points with at least a 12-week interval
<b>Intracerebral haemorrhage</b>		
Sporadic small vessel disease		
Deep perforating vasculopathy	Traditional vascular risk factors (eg, hypertension); preceding cognitive decline	Deep intracerebral haemorrhage (basal nuclei, thalamus, cerebellum, internal capsule); lobar intracerebral haemorrhage; deep microbleeds, lobar microbleeds, or both; no superficial siderosis
Cerebral amyloid angiopathy	Older than 55 years; transient focal neurological episodes; preceding cognitive decline	Haemorrhagic spectrum: lobar intracerebral haemorrhage; strictly lobar microbleeds; superficial siderosis. Ischaemic spectrum: covert MRI markers of small vessel disease
Macrovascular causes		
Cerebral arteriovenous malformation	Absence of traditional vascular risk factors; often younger than 70 years	Flow voids in abnormal regions; calcifications in the arteriovenous malformation
Dural arteriovenous fistula	Absence of traditional vascular risk factors; often younger than 70 years	Flow voids in abnormal regions; often abnormal, dilated cortical veins
Cerebral cavernous malformation	Absence of traditional vascular risk factors; often younger than 70 years	Small intracerebral haemorrhage; so-called popcorn appearance on MRI; other cerebral cavernous malformations that have not bled might be present
Other causes		
Cerebral venous thrombosis	Absence of traditional risk factors; headaches preceding intracerebral haemorrhage onset; onset in pregnancy and postpartum; subacute presentation of neurological signs, epileptic seizures	Haemorrhage location close to sinuses or veins; perihematoma oedema; associated convexity subarachnoid haemorrhage (cortical vein thrombosis)
Reversible cerebral vasoconstriction syndrome	Absence of traditional risk factors; headaches preceding intracerebral haemorrhage onset (typically thunderclap); onset in pregnancy and postpartum; use of vasoactive medication or illicit drugs; subacute presentation of neurological signs, epileptic seizures	Multiple intracerebral haemorrhages; lobar intracerebral haemorrhage location; associated convexity subarachnoid haemorrhage; arterial constriction
Tumour (primary or metastasis)	Absence of traditional risk factors; headaches preceding intracerebral haemorrhage onset; subacute presentation of neurological signs, epileptic crises	Nodular aspect of the haemorrhage; disproportionate perihemorrhagic oedema
*Three or more miscarriages, intrauterine death, prematurity due to high blood pressure, pre-eclampsia, haemolysis, elevated liver enzymes, and low platelets (HELLP)-syndrome, or placenta failure. †Lupus anticoagulant, anti-beta-2 glycoprotein, and anticardiolipin antibodies.		
<b>Table: Clinical, radiological, and diagnostic clues to the underlying causes of ischaemic stroke and intracerebral haemorrhage</b>		

## Epidemiology—global burden of stroke

Stroke poses an enormous challenge to health-care systems worldwide, but especially in LMICs (where 90% of all stroke-related deaths and disability occur, coupled with a surge in stroke incidence) compared with high-income countries.<sup>7</sup> Stroke is the second leading cause of death globally, with almost 7 million deaths worldwide, and is the third leading cause of disability. In 2019, there were over 100 million patients who had a stroke and 12 million new stroke cases globally. Both the incidence (6.4 million vs 5.8 million) and prevalence (56.4 million vs 45.0 million) of all strokes was higher in women than men.<sup>7</sup> There are reports that this worrisome sex difference becomes even more pronounced as women might have poorer access to endovascular therapy and also have lower poststroke functional outcomes;<sup>8</sup> however, there are still many knowledge gaps on the causes and interpretation of these sex differences. The global absolute incidence of stroke increased by 70% and the prevalence by 85% between 1990 and 2019.<sup>7</sup> This increase was partly due to population growth and ageing.<sup>7</sup> However, there is a concern over the increasing age standardised incidence of ischaemic stroke in people between 18 and 50 years, which increased by 50% over the last decade.<sup>9</sup>

Possible explanations for the increased incidence in stroke in young patients are two-fold. First, advanced neuroimaging techniques, particularly diffusion-weighted MRI, might simply result in better stroke detection and more sensitive diagnosis, reducing the risk of misclassification. Second, there is an increased prevalence of modifiable traditional vascular risk factors among young people, such as obesity, diabetes, and increased use of illicit and recreational drugs worldwide, which is a known cause of stroke.<sup>10</sup> The yearly incidence of ischaemic stroke varies between less than 41 per 100 000 people in HICs to more than 150 per 100 000 in LMICs; for intracerebral haemorrhage these figures are less than 15 per 100 000 people in HICs and over 97 per 100 000 people in LMICs.<sup>7</sup> Major contributors to stroke in LMICs are the high prevalence of vascular risk factors such as (uncontrolled) hypertension, diabetes, obesity, smoking, poor diet, and lack of physical exercise as well as poor access to primary care facilities or general practitioners. However, reliable data on the epidemiology of stroke in LMICs are scarce. As most strokes occur in these countries, investigating causes and both short-term and long-term consequences of stroke should be a priority for future research. Over 90% of all ischaemic strokes are attributed to these treatable and preventable risk factors.<sup>11</sup> Apart from these conventional vascular risks, it has become increasingly clear that environmental factors such as lead exposure, ambient air pollution (more serious in LMICs than in the HICs), and extremes of atmospheric temperature<sup>7</sup> are also important risks for stroke. Evidence suggests an escalated risk for stroke after short-term (days) and long-term (years) exposure to air pollution.<sup>12</sup>

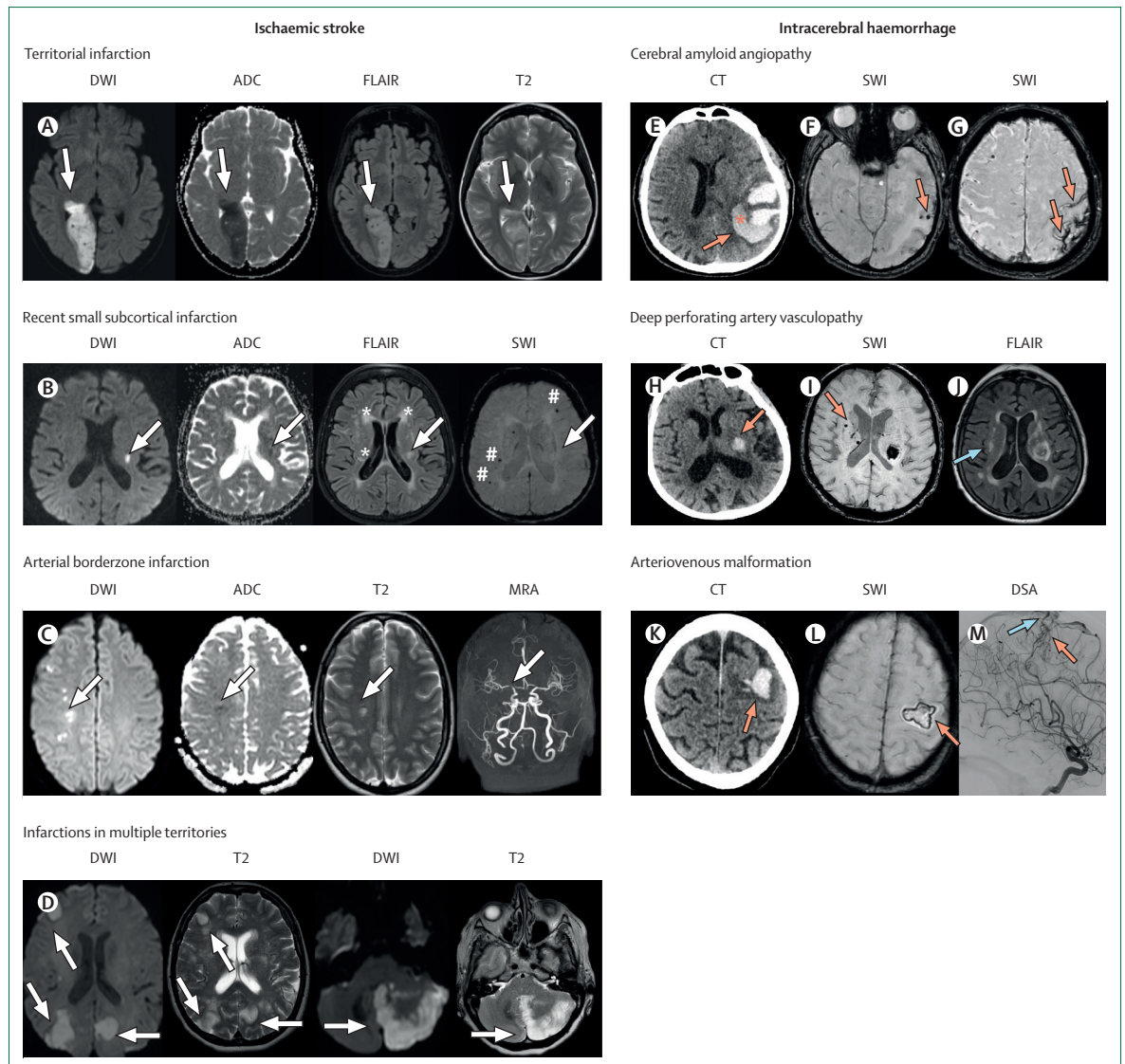
## Pathophysiology and diagnostic workup of ischaemic stroke

Identification of the cause of stroke is central to secondary prevention (table). Investigations should identify individual stroke mechanisms. TOAST is one of the ischaemic stroke classification schemes<sup>13</sup> and the four major categories are: large artery atherosclerosis (artery-to-artery thromboembolism from atherosclerotic lesions of internal carotid artery or intracranial major arteries); embolism from the heart; small vessel disease (occlusion of lenticulostriate arteries or vertebrobasilar perforators); and other causes, including arterial dissection, prothrombotic states, paraneoplastic conditions, infections (including infective endocarditis, neurosyphilis, and tuberculous meningitis), autoimmune vasculitis, hereditary causes, and hormonal treatment, including oral contraception. In young people, there is a substantial proportion of patients who have a stroke of an undetermined cause (cryptogenic strokes).

Infarct topography could provide clues to the underlying pathophysiology of ischaemic stroke (figure 1). Acute infarcts present concomitantly in bilateral hemispheres, or in both anterior and posterior circulations (without fetal posterior cerebral artery), are highly suggestive of cardioembolism (atrial fibrillation or infective or marantic endocarditis). A wedge-shaped territorial infarct points to a proximal vascular occlusion (commonly at distal internal carotid artery or a main trunk of a cerebral artery) and warrants cardiac monitoring for atrial fibrillation and imaging investigation for ipsilateral carotid artery disease. Border zone infarction can appear as single or multiple ischaemic lesions in the watershed region between two major cerebral arteries where the perfusion is the lowest, commonly due to hypotensive episodes (eg, hypovolaemic shock, septic shock, or both, or during general anaesthesia) or large artery steno-occlusive disease (high-grade carotid artery disease, intracranial atherosclerotic disease, or Moyamoya syndrome or disease). In cases of Moyamoya disease there is no underlying cause; in cases of Moyamoya syndrome, there is an underlying cause (eg, neurofibromatosis, trisomy 21, irradiation). Subcortical infarcts due to occlusion of a single penetrating arterial branch are typically small (2–15 mm) and present in the basal ganglia and brainstem. These infarcts are most often caused by small vessel disease, although small emboli could potentially also occlude these perforators.

## Diagnostic investigations

Investigations into the cause of ischaemic stroke should include blood tests for lipid profile and glycaemic control, blood pressure assessment, imaging of the brain (CT or MRI), ultrasonography of intracranial and cervical arteries, CT angiography, or magnetic resonance angiography, and Holter monitor examination or telemetry for at least 48 h to detect possible atrial fibrillation and concurrent cardiovascular morbidities. In young patients without conventional cardiovascular



**Figure 1: Patterns of ischaemic stroke and intracerebral haemorrhage**

Arrows in panels A–D indicate areas of cerebral ischaemia. (A) Territorial infarction caused by posterior artery occlusion. (B) Recent small subcortical infarction (lacunar stroke) due to small vessel disease based on MRI markers of SVD (\*WMH; #microbleed). (C) Borderzone infarction due to high grade stenosis of the distal internal carotid artery caused by Moyamoya disease (MRA scan). (D) Territorial infarctions in multiple arterial territories (left and right middle cerebral artery [anterior circulation] and left posterior inferior cerebellar artery [posterior circulation]), highly suggestive of cardioembolism. (E) Lobar left temporoparietal intracerebral haemorrhage (red arrow), in a patient with cerebral amyloid angiopathy with finger-like projections (asterisk) on brain CT scan according to Edinburgh diagnostic criteria. These features are associated with MRI markers including lobar brain microbleeds (F, red arrow) and cortical superficial siderosis, appearing as hypointensities on the superficial cortex, involving adjacent sulci, according to Boston diagnostic criteria (G, red arrow). Intracerebral haemorrhage (H, red arrow) in the left thalamus with internal capsule involvement, most likely resulting from a deep perforating artery vasculopathy, a common form of small vessel disease. MRI markers of SVD include cerebral microbleeds in the basal ganglia (deep location), appearing as a small area of signal void on SWI shown in panel I (red arrow) and white matter hyperintensities of presumed vascular origin on MRI FLAIR images (panel J, blue arrow). Lobar right frontal intracerebral haemorrhage can be seen in panel K (red arrow), visualised in the hyperacute acute phase (<4 h), with peripheral hypointense signal on SWI sequences (L, red arrow) and a nidus of an underlying left frontal arteriovenous malformation on digital subtraction angiography (M, DSA, red arrow), draining into the superior sagittal sinus via cortical veins (M, blue arrow). ADC=apparent diffusion coefficient. DWI=diffusion-weighted imaging. FLAIR=fluid-attenuated inversion recovery. SVD=small vessel disease. SWI=susceptibility weighted image. WMH=white matter hyperintensities.

risks, ischaemic stroke can be precipitated by anti-phospholipid syndrome, autoimmune disease, use of oral contraceptives, or illicit drugs (amphetamine, cocaine, and cough-mixture abuse).<sup>10</sup> Hereditary stroke disorders (cerebral autosomal dominant arteriopathy

with subcortical infarcts and leukoencephalopathy, cerebral autosomal recessive arteriopathy with subcortical infarcts and leukoencephalopathy, Fabry disease, mitochondrial disease, etc) should be considered when ischaemic stroke runs within families.<sup>14</sup> Genome-

wide association studies have identified some common genetic variants associated with different ischaemic stroke subtypes (eg, large artery or cardioembolic stroke).<sup>15,16</sup>

### Pathophysiology and diagnosis of intracerebral haemorrhage

Spontaneous (non-traumatic) intracerebral haemorrhage is a multifactorial disease, with diverse underlying causes (table, figure 1). The rupture of small arteries initially results in brain damage due to the haematoma mass effect.<sup>17,18</sup> During the first hours, one in three patients have haematoma expansion, sometimes leading to hydrocephalus, raised intracranial pressure, or both, that can result in brain herniation.<sup>19</sup> Bleeding triggers delayed molecular mechanisms (including microglia activation, influx of inflammatory cells, thrombin-induced toxicity, and iron-induced toxicity<sup>20</sup>) that promote blood–brain barrier breakdown and contribute to vasogenic and cytotoxic perihæmatoma oedema development that can present from a few days to a few weeks after intracerebral haemorrhage.<sup>21,22</sup>

In approximately 80% of non-traumatic intracerebral haemorrhage, vessel rupture is caused by sporadic cerebral small vessel disease. There are two main forms of sporadic small vessel disease: deep perforating artery vasculopathy and cerebral amyloid angiopathy.<sup>23</sup>

Small (50–400 µm) perforating arteries are vulnerable to the effects of vascular risk factors, especially hypertension. The resultant progressive deposition of fibrinoid material in the vessel wall (ie, arteriosclerosis) weakens the vessel wall with a consequent increased risk of rupture. In cerebral amyloid angiopathy, deposition of amyloid  $\beta$  (A $\beta$ ) protein affects small and medium sized arterioles; the A $\beta$  protein perforates the cerebral and cerebellar cortex and leptomeninges, with consequent arterial wall thickening, vasoreactivity loss, and focal fragmentation. Cerebral amyloid angiopathy typically causes only lobar (or superficial cerebellar) haemorrhages; deep perforating artery vasculopathy can cause both deep and lobar haemorrhages. Sometimes, different small vessel disease subtypes might overlap.<sup>24</sup>

Other causes of intracerebral haemorrhage include macrovascular malformation (arteriovenous malformations, aneurysms, dural arteriovenous fistula, cerebral cavernous malformation), cerebral venous thrombosis, and reversible vasoconstriction syndrome.<sup>25–27</sup> Underlying primary brain or metastatic tumours can cause intracerebral haemorrhage and should be suspected in case of extensive perihæmatoma oedema. A differential diagnosis is haemorrhagic transformation of ischaemic lesions, mainly in patients with infective endocarditis, vasculitis, or posterior reversible encephalopathy syndrome. Clotting factor deficiency (eg, haemophilia) can also precipitate brain bleeding, but like oral anticoagulants should not be considered as a direct cause of intracerebral haemorrhage.<sup>28</sup>

### Diagnostic investigations

Intracerebral haemorrhage can occur as the consequence of different, sometimes overlapping, vascular and brain pathologies, but a validated unifying causal classification system is still missing.<sup>24</sup> A standard diagnostic investigation should, apart from history taking and evaluation of vascular risk factors, include brain imaging (preferably with MRI) for every patient with an intracerebral haemorrhage. Macrovascular causes underlying intracerebral haemorrhage should be excluded in patients aged under 70 years with either CT angiography, magnetic resonance angiography, or digital subtraction angiography, especially in the absence of arterial hypertension and radiological markers of small vessel disease. Underlying small vessel disease as the cause of intracerebral haemorrhage can be investigated by identifying MRI markers of small vessel disease, as the pathology of small cerebral arteries cannot be visualised with neuroimaging. Despite high costs and limited accessibility, brain MRI allows more accurate identification of the underlying causes of intracerebral haemorrhage. Updates to the diagnostic criteria for cerebral amyloid angiopathy and small vessel disease biomarkers have been published.<sup>28–30</sup>

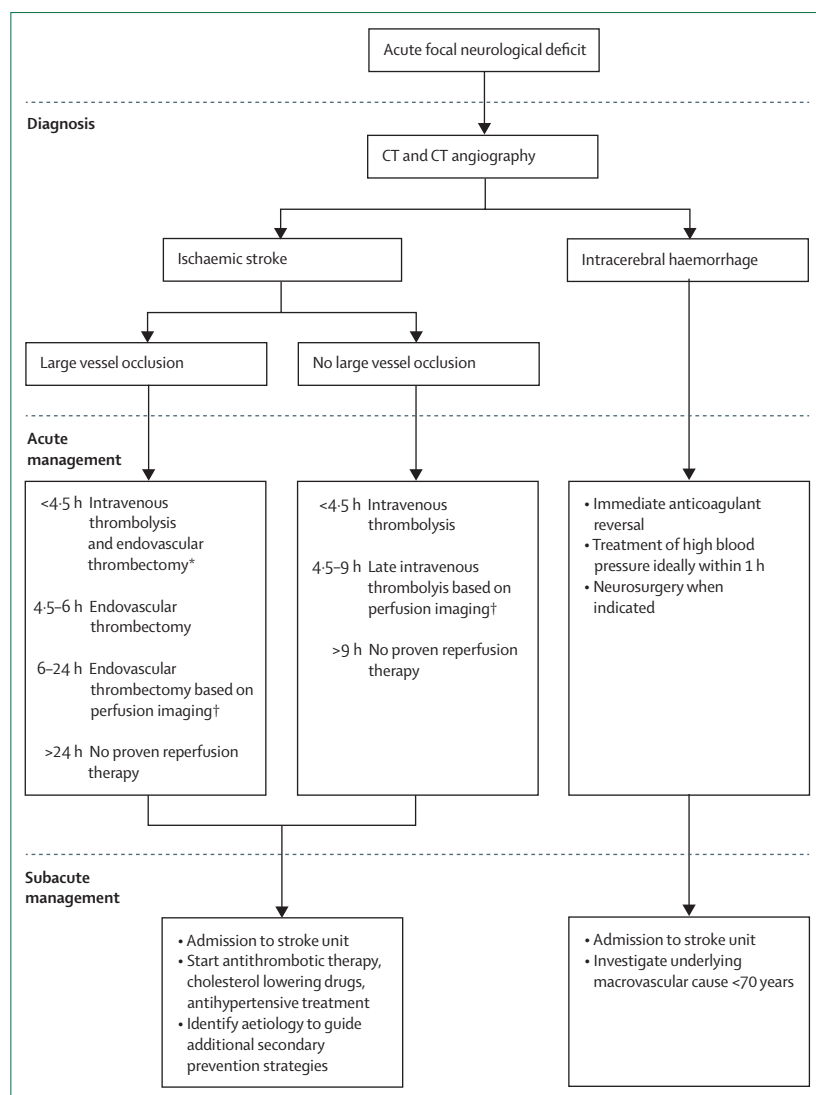
CT angiography and magnetic resonance angiography showed greater than 90% sensitivity and specificity for detecting macrovascular causes of intracerebral haemorrhage.<sup>27</sup> Diagnostic digital subtraction angiography remains the gold standard in patients younger than 45 years with any intracerebral haemorrhage location and in patients younger than 70 years with lobar intracerebral haemorrhage, without any vascular risk factors or signs of cerebral small vessel disease.<sup>25–27,31,32</sup> According to clinical and radiological presentation (table), other intracerebral haemorrhage causes should be ruled out as they require urgent therapeutic management. These include reversible cerebral vasoconstriction syndrome and cerebral venous thrombosis, which requires CT angiography, magnetic resonance angiography, digital subtraction angiography, or CT venography or magnetic resonance venography.<sup>25,33</sup> Repeating contrast CT or MRI and vascular imaging 3 months after intracerebral haemorrhage helps to exclude a mass, lesion, or vascular malformation that was initially compressed by the intracerebral haemorrhage, and to verify intracerebral haemorrhage resorption.

### Acute treatment for ischaemic stroke

The goal of acute ischaemic stroke management is to restore cerebral perfusion as soon as possible with intravenous thrombolysis, endovascular thrombectomy, or both, followed by admission to a dedicated stroke care facility (figure 2).

### Prehospital stroke management

As substantial delays occur in the pre-hospital phase, the primary objective of prehospital stroke management is to



**Figure 2: Stroke management flowchart**

FLAIR=fluid-attenuated inversion recovery. \*In case of contraindications to intravenous thrombolysis, only endovascular thrombectomy should be performed. †Diffuse-weighted imaging-FLAIR mismatch or CT-perfusion mismatch. There is a shift towards selection of patients for endovascular thrombectomy between 6 to 24 h based on non-contrast CT alone, however this is not incorporated into guidelines yet.

expedite reperfusion therapies. The BE FAST test (balance, eyes, face, arm, speech, time) helps to quickly recognise the symptoms of a stroke<sup>34</sup>—and in the era of endovascular thrombectomy, field assessments like the Field Assessment Stroke Triage for Emergency Destination (FAST-ED) that incorporates cortical signs (eg, aphasia, eye deviation, and denial or neglect) is crucial to identify possible large vessel occlusion strokes.<sup>35</sup> Yet administration of the National Institutes of Health Stroke Scale (NIHSS) prehospitally by paramedics did not improve triage further.<sup>36</sup> Of note, these screening tools discriminate poorly between ischaemic strokes and intracerebral haemorrhage. As a result, thrombectomy-capable hospitals that directly admit patients with

suspected large vessel occlusion from emergency sites could be burdened by an increased number of hemorrhagic strokes.

Individuals with suspected large vessel occlusion strokes or contraindications to intravenous thrombolysis might benefit from direct transfer to thrombectomy-capable centres, bypassing the nearest primary stroke centre (ie, the mothership model), even if this causes some transport delays.<sup>37</sup> However, randomised clinical trials investigating transport strategy models in patients with suspected acute large vessel occlusion stroke were either prematurely halted before full recruitment<sup>38</sup> or did not report a significant difference in 90-day neurological outcomes between direct transportation to thrombectomy-capable centre or local stroke centre in non-urban areas of Spain.<sup>39</sup> The optimal referral strategy likely depends on the regional organisation of health care, the probability of large vessel occlusion, and interhospital transport delays.

Mobile stroke units have been established to shorten the time between an emergency call and beginning intravenous thrombolysis. A mobile stroke unit is an ambulance with a CT scanner, a telemedicine system, and a point of care laboratory system, staffed with a nurse and a paramedic, with or without an onboard physician. The mobile stroke unit can deliver intravenous thrombolysis at the emergency site, reducing the time between stroke onset and intravenous thrombolysis. Moreover, patients diagnosed with large vessel occlusion by onboard CT angiography can be directly transferred to a thrombectomy-capable centre. Compared with usual care, use of a mobile stroke unit was associated with an approximately 65% increase in the chance of an excellent outcome and a 30 min reduction in stroke onset to intravenous thrombolysis times without safety concerns.<sup>40</sup> Nevertheless, a mobile stroke unit requires substantial financial investment, with its effectiveness depending on local geography. Overall, prehospital stroke management should be organised based on a regional hub and spoke network basis, considering interhospital distances, geographical barriers, and the cost-effectiveness of triage and patient diversion systems.

### Intravenous thrombolysis with alteplase or tenecteplase

Alteplase is currently the only thrombolytic agent approved by all regulatory agencies for acute ischaemic strokes.<sup>41,42</sup> Upon exclusion of intracerebral haemorrhage by non-contrast brain CT, alteplase at 0.9 mg per kg (10% bolus followed by 90% infused in 1 h; maximum 90 mg) reduced stroke-related disability.<sup>43</sup> Current guidelines recommend intravenous thrombolysis within 4.5 h after stroke onset, and the number needed to treat for intravenous thrombolysis to achieve one additional patient with excellent functional outcome (modified Rankin Scale [mRS] 0–1) is time-dependent; 10 within 3 h after stroke onset, and 19 from 3–4.5 h.<sup>44,45</sup> The absolute risk of fatal intracerebral haemorrhage was

approximately 2%.<sup>46</sup> The benefit of alteplase was less clear in patients with non-disabling stroke symptoms.<sup>47,48</sup>

Tenecteplase is a genetically modified variant of alteplase that allows intravenous thrombolysis in a single bolus in seconds without subsequent infusion. Although tenecteplase is currently only approved for acute myocardial infarction by the US Food and Drug Administration (FDA), it has been frequently used off-label in acute ischaemic strokes.<sup>41</sup> For patients who have had an ischaemic stroke with a duration of less than 4.5 h who are eligible for intravenous thrombolysis, tenecteplase 0.25 mg per kg (maximum 25 mg) is now considered as a safe and effective alternative to alteplase 0.9 mg per kg.<sup>49–55</sup> The rate of symptomatic intracerebral haemorrhage of tenecteplase at 0.25 mg per kg was comparable to alteplase 0.9 mg per kg. In prehospital thrombolysis by a mobile stroke unit, tenecteplase 0.25 mg per kg for patients with ischaemic stroke with a duration of less than 4.5 h enhanced early reperfusion rate.<sup>56</sup>

For patients with acute large vessel occlusion stroke of with a duration of less than 4.5 h who are eligible for both intravenous thrombolysis and endovascular thrombectomy, tenecteplase 0.25 mg per kg (maximum 25 mg) enhanced recanalisation rates before and at the end of the endovascular thrombectomy.<sup>49,50,57,58</sup> However, it was not associated with better functional outcome at 90 days in patients with wake-up stroke selected by non-contrast CT.<sup>59</sup>

### Intravenous thrombolysis in extended time-window

In general, infarct core progresses with time from stroke onset, but the pace of progression varies among patients. Therefore, ideally an individual tissue clock rather than a fixed time window should determine eligibility of reperfusion therapies. Advanced imaging (CT or MRI perfusion) could act as such a clock and was used to identify patients with salvageable brain tissue 9 h from symptom recognition.<sup>60,61</sup> This subset of patients had as much benefit from intravenous thrombolysis, with similar risk of fatal intracerebral haemorrhage, as did those treated within 3 h from stroke onset. Alternatively, if patients with unknown stroke onset time (or wake-up stroke) had diffuse-weighted imaging-positive lesions indicative of acute ischaemia that were not yet hyperintense on fluid-attenuated inversion recovery (FLAIR) sequence (eg, diffuse-weighted imaging–FLAIR mismatch), the stroke onset was likely to be within 4.5 h, and they might benefit from alteplase.<sup>62</sup> However, the constrained MRI service in many regions might reduce the applicability of this technique.

### Endovascular thrombectomy and acute stroke treatment

In 2015, endovascular thrombectomy was shown to reduce disability and mortality for ischaemic strokes attributed to acute large vessel occlusion.<sup>63–68</sup> The number

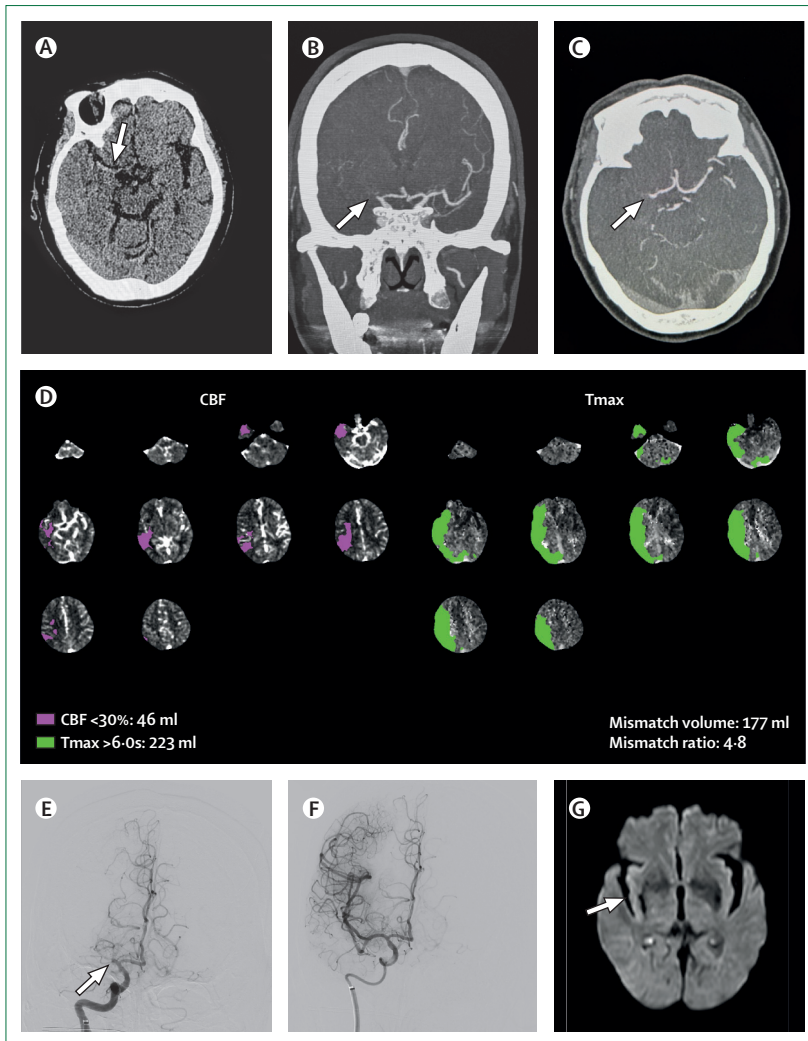
of patients needed to treat to reduce disability by at least one level on the mRS for one patient was 2.6; patients younger than 80 years and those not qualifying for intravenous thrombolysis also benefit from endovascular thrombectomy.<sup>68</sup>

The treatment window of endovascular thrombectomy has been extended to 24 h from symptom onset on the basis of imaging evidence of salvageable brain tissue<sup>69,70</sup> or collateral flow.<sup>71,72</sup> In a meta-analysis of endovascular thrombectomy trials using a 6–24 h window, endovascular thrombectomy was associated with higher rates of independent daily living (mRS 0–2) without increasing intracerebral haemorrhage or mortality compared to medical treatment, and while there was no heterogeneity of treatment effect noted across subgroups defined by age, gender, baseline stroke severity, vessel occlusion site, baseline Alberta Stroke Program Early CT Score, or mode of presentation, treatment effect was stronger in patients randomly assigned within 12–24 h than those randomly assigned within 6–12 h.<sup>72</sup>

Although patients with large vessel occlusion and large core infarcts were excluded in early trials, randomised studies have found meaningful clinical benefits of endovascular thrombectomy in this subgroup of patients.<sup>73–76</sup> A pooled analysis showed that compared with medical therapy alone, endovascular thrombectomy for patients with extensive ischaemic injury selected on non-contrast CT, CT perfusion, or MRI was associated with a higher likelihood of reduced disability, independent ambulation, and good functional outcome at 3 months.<sup>77</sup> In practice, treatment decisions for patients with large core infarcts need to be individualised and consider patients' comorbidities. Figure 3 depicts large vessel occlusion, salvageable brain tissue, and restoration of cerebral blood flow after endovascular thrombectomy.

For posterior circulation large vessel occlusion, two studies have shown improved functional outcomes at 90 days in patients with basilar artery occlusion with endovascular thrombectomy compared with medical treatment, although endovascular thrombectomy was associated with procedural complications and intracerebral haemorrhage.<sup>78,79</sup> A meta-analysis suggested the overall benefit of endovascular thrombectomy in acute basilar artery occlusion up to 24 h.<sup>80</sup> However, the treatment benefit in individuals with basilar artery occlusion with milder deficits (NIHSS <10) remained uncertain.

Although stroke guidelines emphasise that intravenous thrombolysis should not delay endovascular thrombectomy, there is no strong evidence that intravenous thrombolysis should be skipped in patients with large vessel occlusion.<sup>81–86</sup> Therefore, for stroke patients with anterior circulation large vessel occlusion who are admitted directly to a centre capable of endovascular thrombectomy within 4.5 h of symptom onset and who are eligible for both treatments, current guidelines recommend both intravenous thrombolysis and



**Figure 3: Ischaemic stroke due to large vessel occlusion**

CT performed 43 min after stroke onset showed no haemorrhage or early infarct changes, but a dense middle cerebral artery sign on the right (arrow) and an electrocardiogram revealed atrial fibrillation (A). CT angiography showed an occluded right middle cerebral artery (arrows in coronal and axial views; B and C). CT perfusion revealed imaging evidence of salvageable brain tissue with a mismatch ratio of 4.8 between ischaemic penumbra volume (223 mL, the region in green where Tmax delay > 6 s) and infarct core volume (46 mL, the region in purple where cerebral blood flow <30%) in right middle cerebral artery territory (D). After intravenous tenecteplase (0.25 mg/kg) and endovascular thrombectomy, the occluded right middle cerebral artery (E, arrow) was recanalised (F) and the neurological deficits largely resolved. The door-to-reperfusion time was 60 min. Subsequent diffuse-weighted MRI showed residual infarction over the right insular region (G, arrow). The patient resumed full independence in daily activities in a week and was discharged home with oral anticoagulants. Tmax=time-to-maximum.

endovascular thrombectomy. In stroke patients with anterior circulation large vessel occlusion admitted to a primary stroke centre and eligible for intravenous thrombolysis (symptom onset  $\leq 4.5$  h) and endovascular thrombectomy, guidelines recommend intravenous thrombolysis followed by rapid transfer to endovascular thrombectomy-capable centres. During postendovascular thrombectomy care, intensive control of systolic blood pressure to lower than 120 mm Hg should be avoided to prevent compromising the patients' functional recovery.<sup>87,88</sup>

### Acute treatment for intracerebral haemorrhage

In the early hours after intracerebral haemorrhage onset, therapeutic options aim to limit haematoma expansion in an attempt to prevent complications and poor clinical outcomes.<sup>19</sup> Although studies on single interventions during the acute phase of intracerebral haemorrhage did not show benefit on functional outcomes, the implementation of a bundle of care (consisting of immediate simultaneous anticoagulation reversal, blood pressure management, and prespecified stroke unit protocols [including glucose control and antipyretics]) within 6 h after intracerebral haemorrhage onset improved both survival rates and functional outcome at 6 months.<sup>89,90</sup> Accordingly, implementation of an acute bundle of care concept, combining a rapid anticoagulation reversal, intensive blood pressure reduction, surgery, and easy access to critical care, was significantly associated with lower mortality rates 30 days after intracerebral haemorrhage.<sup>91</sup>

The immediate reversal of anticoagulation improves survival after intracerebral haemorrhage, yet its benefit on functional outcomes is uncertain. The recommended pharmacological anticoagulation reversal strategy includes 4-factor prothrombin complex concentrate (in preference to fresh frozen plasma) and intravenous vitamin K for vitamin K antagonist-associated intracerebral haemorrhage; protamine for unfractionated and low molecular weight heparin reversal; andexanet alfa to antagonise factor Xa inhibitors; and idarucizumab to reverse the effects of dabigatran.<sup>92–102</sup> When specific medications to manage anticoagulation reversal are not available, prothrombin complex concentrate can improve haemostasis. For patients taking antiplatelets without the need for neurosurgery, platelet transfusion is potentially harmful.<sup>103</sup> Other haemostatic therapies, including recombinant activated factor VII<sup>104,105</sup> and tranexamic acid,<sup>106–111</sup> have not shown benefit on functional outcome.

Current recommendations advocate for blood pressure reduction as soon as possible to a systolic target of approximately 140 mm Hg, with titration for a smooth and sustained control ideally within 1 h.<sup>25,112</sup> Reducing systolic blood pressure to less than 130 mm Hg is potentially harmful and should be avoided.<sup>113,114</sup> Intravenous antihypertensive drugs with rapid action and short half-life, such as nicardipine or labetalol, facilitate blood pressure titration—but venous vasodilators like transdermal glyceryl nitrate might be harmful.<sup>115</sup> Despite guideline recommendations, the benefit of intensive blood pressure reduction on functional outcomes after acute intracerebral haemorrhage has been inconsistent across randomised controlled trials, posthoc analyses, and meta-analyses.<sup>113,116–123</sup>

In patients with infratentorial intracerebral haemorrhage who deteriorate clinically from hydrocephalus or brainstem compression, external ventricular drainage and neurosurgical removal of large (>3 cm) cerebellar haematomas reduces mortality compared with medical

treatment alone.<sup>25</sup> For supratentorial intracerebral haemorrhage, studies on craniotomy with surgical evacuation have not shown clinical benefit.<sup>124–129</sup> Current recommendations suggest that minimally invasive surgery, with or without thrombolytic use, can reduce mortality for patients with a Glasgow coma scale between 5 and 12 due to large supratentorial intracerebral haemorrhage (>20–30 mL), compared with conservative management, although its benefit on functional outcomes is uncertain.<sup>130–136</sup> Minimally invasive surgery compared to conventional craniotomy could improve functional outcomes but the benefit on mortality reduction is similarly uncertain. The optimal timing for surgery remains controversial because early intervention (<12–24 h) can increase the risk of rebleeding despite the objective to reduce secondary brain injury and perihematomal oedema.<sup>137</sup> Randomised controlled trials addressing these questions are underway and extend to other techniques such as decompressive hemicraniectomy.

### Stroke unit

In a stroke unit, patients are treated by an integrated, multidisciplinary team of medical, nursing, and allied health stroke experts. Stroke unit care has clearly shown to improve survival and diminish stroke-related disability for patients of all ages, severities, and stroke subtypes.<sup>138</sup> Crucial components of stroke unit care include swallowing assessment and training to minimise aspiration pneumonia; timely management of fever, sepsis (if present), and glucose; early mobilisation and rehabilitation; pressure sore prevention; deep venous thromboembolism prophylaxis; and targeted secondary stroke prevention.<sup>139</sup> Admission to a stroke unit also warrants the early detection and management of neurological complications such as haemorrhagic transformation of an ischaemic stroke, early seizures, delirium, early recurrent stroke, or the development of cerebral oedema (including a space occupying middle cerebral artery infarction). Surgical decompression performed within 48 h of stroke onset could reduce the risks of death or a poor outcome in patients 60 years or younger.<sup>140</sup> With the exception of surgical decompression, other treatments of early poststroke complications are only based on empirical recommendations and this is an area requiring future research.<sup>141</sup>

### Secondary prevention

Secondary prevention demands prompt diagnostic workup for the underlying stroke cause, early identification of modifiable risk factors, and life-long compliance to treatment. The strategy encompasses antiplatelet therapy for non-cardioembolic ischaemic strokes, oral anticoagulation for cardioembolic strokes, treatment of hypertension, diabetes, and hyperlipidaemia, as well as lifestyle adjustments, including smoking cessation, promotion of physical activity, a healthy diet, and weight management for obesity.

### Antithrombotic therapy after ischaemic stroke

Antithrombotic therapy is indicated for almost all patients after an ischaemic stroke, either with oral anticoagulants for patients with atrial fibrillation, or antiplatelet agents after non-cardioembolic causes of stroke. For minor strokes, initiation of antiplatelet therapy as early as possible after the first day of symptom onset reduces 90 day stroke recurrence.<sup>142</sup> In case of a non-cardioembolic minor stroke, a short course of dual antiplatelet therapy (clopidogrel and aspirin) initiated within 24 hours and lasting between 21 and 90 days is more effective in reducing recurrent vascular events than aspirin alone.<sup>143–145</sup> The benefit in preventing early relapse is still evident when dual antiplatelet agents were commenced within 72 h.<sup>146</sup> Likewise, the combination of ticagrelor and aspirin for 30 days provides benefit over aspirin monotherapy for prevention of stroke.<sup>147</sup> Approximately a quarter of White patients and 60% of Asian patients have a genetic variant in *CYP2C19*, resulting in reduced conversion of clopidogrel into its active metabolite.<sup>148,149</sup> It is unclear whether this reduced platelet inhibition by clopidogrel is synonymous with higher stroke recurrence. In Chinese patients with *CYP2C19* loss of function, the combination of ticagrelor with aspirin was more effective in reducing recurrent stroke within the first 90 days than clopidogrel with aspirin.<sup>150,151</sup> For long-term secondary prevention, clopidogrel, aspirin, or aspirin-dipyridamole are recommended as first-line agents. The addition of cilostazol to clopidogrel or aspirin after atherothrombotic stroke showed promising results among Japanese patients,<sup>152</sup> and warranted further study in other populations.<sup>153</sup> There is no indication for direct oral anticoagulants in patients with embolic stroke of undetermined source (ESUS, defined as non-lacunar ischaemic stroke without an obvious cause after standard evaluation).<sup>154,155</sup>

Oral anticoagulants are indicated for patients with non-valvular atrial fibrillation, with direct oral anticoagulants preferred over vitamin K antagonists due to a two-fold lower risk of intracranial haemorrhage.<sup>156</sup> The optimal time to start oral anticoagulation after ischaemic stroke has been addressed in randomised clinical trials, which reported that oral anticoagulation started 48 h after a minor to moderate ischaemic stroke or on day 6 or 7 after a major ischaemic stroke appears safe without exacerbating haemorrhagic transformation, although these results are yet to be stipulated in published guidelines.<sup>157,158</sup>

### Management of vascular risk factors

Hypertension is a major modifiable risk factor for both ischaemic stroke and intracerebral haemorrhage. Blood pressure control after ischaemic stroke to less than 130/80 mm Hg reduces risk of recurrent stroke by about 20% compared to less strict targets (140–150/80 mm Hg) and prevents 17 cases of stroke per 1000 patients treated.<sup>159</sup> Greater reductions in systolic

and diastolic blood pressure appear to be linearly related to lower risk of recurrent stroke,<sup>160</sup> although it is unclear whether there is an optimal lower limit.<sup>161</sup> The magnitude of blood pressure reduction appears more important than the class of antihypertensive medication used.<sup>162</sup> The optimal timing of treatment initiation is uncertain; early blood pressure reduction within 7 days of an ischaemic stroke was not superior to deferred blood pressure control in terms of death or dependency.<sup>163</sup>

LDL cholesterol reduction lowers overall recurrent risk. A target of less than 1.8 mmol per L provides additional benefit over a less stringent target of 2.3–2.8 mmol per L among patients with evidence of atherosclerosis.<sup>164</sup> Adjunctive use of ezetimibe, PCSK9 inhibitors, or both is recommended if the LDL target cannot be achieved with statins alone.

For patients with diabetes, a glycated haemoglobin level (HbA<sub>1c</sub>) of less than 53 mmol per mol (or <7%) resulted in a reduced risk of microvascular and macrovascular complications,<sup>165</sup> although an individualised target is indicated if the risk and inconvenience of a strict control outweigh potential benefits. Whether more intensive control of HbA<sub>1c</sub> is beneficial remains uncertain.<sup>166–168</sup> GLP-1 receptor agonists are new antihyperglycaemic drugs that have been shown to improve control of vascular risk factors (HbA<sub>1c</sub> levels, blood pressure, body weight) in patients with diabetes, and reduce risk of stroke by 15%.<sup>169</sup> To date, the benefit of GLP-1 receptor agonists has only been established in patients with diabetes or impaired glucose metabolism, of whom only a minority had a history of stroke; as such, GLP-1 receptor agonists have no role in secondary stroke prevention yet. Various support programmes aimed at improving adherence to secondary prevention strategies resulted in improved control of vascular risk factors but did not translate into a reduction of major vascular events.<sup>170,171</sup> Anti-hypertensive treatment and lifestyle modification are indicated as secondary prevention measures after intracerebral haemorrhage.<sup>25</sup> The ideal target blood pressure is unknown, but a target of 130/80 mm Hg is recommended.

#### Cause specific management of ischaemic stroke

Carotid endarterectomy is recommended for patients with ipsilateral severe (50–99%) carotid artery stenosis and surgery should be done within two weeks of the index stroke. Among patients with 50–69% stenosis, the benefit of carotid endarterectomy is dependent on patient characteristics, carotid endarterectomy symptom interval, comorbidities, and plaque characteristics. Carotid endarterectomy is the preferred type of carotid revascularisation, however after restenosis, previous irradiation or high perioperative risk carotid artery stenting is an alternative. Intracranial atherosclerosis is a frequent cause of stroke among Asian people and is associated with a high risk of early recurrence if the stroke mechanism is thromboembolism and hypoperfusion

combined.<sup>172</sup> Stringent risk factor control and dual antiplatelet therapy for 90 days could be considered.<sup>173</sup> There is no benefit of intracranial angioplasty or stenting adjunctive to optimal medical management.<sup>174,175</sup> The effect of ischaemic preconditioning in patients with intracranial atherosclerosis has been investigated in a randomised trial and showed no effect on risk of recurrent ischaemic stroke.<sup>176</sup>

Closure of patent foramen ovale with a transcatheter device could be considered in patients up to 60 years with non-lacunar cryptogenic stroke who have a patent foramen ovale with a large shunt, atrial septum aneurysm, or both. The high number needed to treat (131 to prevent one recurrent stroke for 1 person-year) and the approximately 5% risk of periprocedural complications including atrial fibrillation should be taken into account.<sup>177,178</sup> Patient selection in these trials was usually done with the Risk of Paradoxical Embolism score, however that does not include (high risk) characteristics of the patent foramen ovale. The patent foramen ovale associated Stroke Causal Likelihood classification scheme does include this by acknowledging the presence of an atrial septum aneurysm and the size of the shunt and shows potential to guide personalised patent foramen ovale closure based on individual patient data meta-analysis.<sup>178</sup>

#### Resumption of antithrombotic therapy after intracerebral haemorrhage

Risk of intracerebral haemorrhage recurrence varies according to the underlying intracerebral haemorrhage cause, reaching 15–20% per year in patients with cerebral amyloid angiopathy with multifocal cortical superficial siderosis and multiple microbleeds.<sup>179,180</sup> However, intracerebral haemorrhage is increasingly recognised as a marker for ischaemic events.<sup>181–184</sup> In patients who have had an intracerebral haemorrhage who also have clinical indications for antiplatelet therapy, resumption of aspirin within 30 days after intracerebral haemorrhage was safe in the RESTART trial.<sup>185–188</sup> Other randomised controlled trials are ongoing to investigate the effect of antiplatelet resumption after intracerebral haemorrhage on safety, reduction of major ischaemic events, overall long-term functional outcome, and optimal timing of resumption.

In patients who have had an intracerebral haemorrhage who also have atrial fibrillation, observational data showed that anticoagulation restarted 4–8 weeks after the intracerebral haemorrhage improved survival and functional outcome, even in patients with cerebral amyloid angiopathy.<sup>189–193</sup> Results of two randomised controlled trials confirmed the safety of restarting oral anticoagulation after intracerebral haemorrhage,<sup>194,195</sup> and several studies are still ongoing.<sup>192,193</sup> Compared with oral anticoagulation, percutaneous left atrial appendage occlusion is an interventional approach that might reduce recurrent intracerebral haemorrhage risk. The overall clinical benefit of left atrial appendage occlusion, including reduction of ischaemic and haemorrhagic risk compared to oral

anticoagulation, is tested in several randomised controlled trials.<sup>196</sup> In patients with mechanical heart valves, early anticoagulant resumption (eg, 1–2 weeks following intracerebral haemorrhage) is recommended, despite limited data from randomised controlled trials, due to the excessive risk of major ischaemic events.<sup>197</sup>

### Life after ischaemic stroke and intracerebral haemorrhage

Cognitive impairment, often resulting in poststroke dementia, mood disorders, and fatigue affects almost every stroke survivor. The tragedy is that these symptoms are often unrecognised and only rarely investigated in clinical trials despite being associated with mortality and poor functional outcome.<sup>198</sup> Trials that have been done are often aimed at improving poststroke functional (often motor) outcomes. The administration of fluoxetine in randomised clinical trials among almost 6000 patients with either ischaemic stroke or intracerebral haemorrhage showed no clinical meaningful effect on functional outcome.<sup>199–201</sup>

Although a review of 45 trials including over 1600 patients with stroke (not otherwise specified) showed that electromechanical arm training and robot-assisted arm training improved arm function, the clinical importance remained uncertain.<sup>202</sup> The effect of device-assisted arm training on functional arm performance could not be confirmed in a subsequent trial.<sup>203</sup> Combined

intensive rehabilitation and vagal nerve stimulation showed promising results on recovery of arm function.<sup>204</sup> Aphasia is among the most debilitating poststroke sequelae, without any proven intervention that resulted in meaningful improvement in conversation.<sup>205</sup> Due to the revolution in the acute treatment of ischaemic stroke many more people survive their stroke, resulting in increasing numbers of patients with accompanying poststroke motor and cognitive disabilities. WHO operationalised intervention packages in specific domains (eg, cognitive function, vision, language, pain, bowel and bladder management, among others) for which targeted interventions exist and should be developed. However, despite these recommendations there currently is a scarcity of evidence-based guidelines in this area.<sup>206</sup> Rigorous research with sound methodological approaches is therefore key to ultimately ameliorate this and ranks high among research priorities of patients.<sup>207</sup>

### Conclusion

There have been major advances in all areas of stroke since the publication of the previous Seminar on stroke in *The Lancet*, with many alluring future perspectives (panel). The acute treatment of ischaemic stroke has revolutionised over the past years, particularly with the advent of imaging-based late intravenous thrombolysis and endovascular thrombectomy. Recent advances again

#### Panel: Recent advancements and future perspectives

##### Major progress since last seminar

###### *Treatment of acute ischaemic stroke*

- Imaging triage and intravenous thrombolysis by mobile stroke units.
- Treatment time window for endovascular thrombectomy extended up to 24 h in patients with large infarct core based on non-contrast CT without penumbra demonstration by CT perfusion.
- Endovascular thrombectomy for basilar artery occlusion up to 24 h.

###### *Treatment of intracerebral haemorrhage*

- Early bundled interventions in the hyperacute phase, including immediate (<1 h from admission) anticoagulant reversal, blood pressure management, and stroke unit admission.

###### *Secondary prevention*

- Early initiation of oral anticoagulants after ischaemic stroke, ranging from within 2 days in mild-moderate stroke to 1 week in severe stroke in patients with atrial fibrillation.
- Growing body of evidence on safety of resumption of antithrombotic therapy (antiplatelet therapy and oral anticoagulants) in patients who have an indication after intracerebral haemorrhage.

##### Future perspectives

###### *Treatment of acute ischaemic stroke*

- Endovascular thrombectomy for medium-sized vessel occlusions.
- Immediate transfer to angiosuite of patients with a high likelihood of large vessel occlusion, with direct endovascular thrombectomy after exclusion of intracerebral haemorrhage on non-contrast CT at angiosuite.

###### *Treatment of intracerebral haemorrhage*

- Tailored (minimally invasive) surgical approach in the acute phase of intracerebral haemorrhage.
- New strategies to improve haemostasis, limit inflammation, and reduce perihematomal oedema.

###### *Secondary prevention*

- New targets for secondary prevention including inflammation and raised lipoprotein levels.
- Antithrombotic treatment with factor XIa inhibitors, which could inhibit thrombus formation more selectively than conventional oral anticoagulants without compromising haemostasis.
- Optimised medical management according to current standards and refrain from carotid revascularisation in patients with an estimated 5-year risk of below 20% of recurrent stroke.

move away from selection of patients for endovascular thrombectomy based on perfusion imaging, given the beneficial effects of endovascular thrombectomy in virtually every patient within 24 h of symptom onset. Acute treatment of intracerebral haemorrhage is the next frontier with acute, minimally invasive surgical techniques as promising options, and the future perspective of additional anti-inflammatory treatment. Although the recurrent risk in some stroke subtypes remains high, the challenge of secondary prevention also lies in long-term treatment adherence. Putting the four important pillars of monitoring and prevention of modifiable risk factors, access to acute stroke treatment, access to stroke units, as well as secondary prevention and rehabilitation on the political and public health-care agenda is key to tackling the global burden of stroke and reducing its immense personal and societal strain, particularly in LMICs.<sup>208</sup>

#### Contributors

All authors contributed equally to the literature search, data collection and their interpretation, writing of the manuscript (original drafts, reviewing and editing each other sections), and visualisation (ie, tables and figures). All authors verified and approved the final version of the manuscript.

#### Declaration of interests

NAH receives research support from the Dutch Heart Foundation (03–005–2022–0031). BC has received research grants from Regional GIRC Méditerranée, Nice University Hospital, Acticor Biotech, and Bayer; support for attending meetings from the European Stroke Organisation, French Neurovascular Society, Belgium Stroke Council, and French Neurology Society; and is an editorial board member of the European Stroke Journal, chair of the European Stroke Organisation (ESO) Simulation Committee, and chair of the Education and Communication committee within StrokeLink (all unpaid). TWL has received support for the present manuscript from the Kwok Tak Seng Centre for Stroke Research and Intervention and the SHKP Kwok Brain Health Research Centre; an educational grant from Boehringer Ingelheim; consulting fees from Shionogi & Co and Janssen Research & Development; honoraria from Daiichi-Sankyo and Argenica Therapeutics; payment for expert testimony; travel expenses from Pfizer, Daiichi-Sankyo, and Boehringer Ingelheim; was a member of the data safety monitoring board for the ENCHANTED2/MT study at The George Institute for Global Health; and is chairman of the exemptions sub-committee, and member of the licentiate committee for The Medical Council of Hong Kong, co-chair of the co-chairs committee for Mission Thrombectomy 2020+ as part of The Society of Vascular Interventional Neurology, associate editor for the *International Journal of Stroke*, assistant editor for the journal *Stroke*, and board member of the specialty board in neurology at Hong Kong College of Physicians (all unpaid). F-EdL received funding from the Dutch Heart Foundation, Abbott, and ZonMW; serves as a member of the scientific advisory board of the Dutch Heart Foundation and is associate editor for the *International Journal of Stroke* (unpaid); and has received registration fees from ESO for the ESO Conference. None of these parties or funders had any influence in any part of the preparation of this Seminar.

#### References

- Sacco RL, Kasner SE, Broderick JP, et al. An updated definition of stroke for the 21st century: a statement for healthcare professionals from the American Heart Association/American Stroke Association. *Stroke* 2013; **44**: 2064–89.
- Saver JL. Proposal for a universal definition of cerebral infarction. *Stroke* 2008; **39**: 3110–15.
- Easton JD, Johnston SC. Time to retire the concept of transient ischemic attack. *JAMA* 2022; **327**: 813–14.
- Moseley ME, Kucharczyk J, Mintorovitch J, et al. Diffusion-weighted MR imaging of acute stroke: correlation with T2-weighted and magnetic susceptibility-enhanced MR imaging in cats. *AJNR Am J Neuroradiol* 1990; **11**: 423–29.
- Vilela P. Acute stroke differential diagnosis: stroke mimics. *Eur J Radiol* 2017; **96**: 133–44.
- Claassen J, Park S. Spontaneous subarachnoid haemorrhage. *Lancet* 2022; **400**: 846–62.
- Feigin VL, Stark BA, Johnson CO, et al. Global, regional, and national burden of stroke and its risk factors, 1990–2019: a systematic analysis for the Global Burden of Disease study 2019. *Lancet Neurol* 2021; **20**: 795–820.
- Ospel JM, Schaafsma JD, Leslie-Mazwi TM, et al. Toward a better understanding of sex- and gender-related differences in endovascular stroke treatment: a scientific statement from the American Heart Association/American Stroke Association. *Stroke* 2022; **53**: e396–406.
- Ekker MS, Verhoeven JI, Vaartjes I, van Nieuwenhuizen KM, Klijn CJM, de Leeuw FE. Stroke incidence in young adults according to age, subtype, sex, and time trends. *Neurology* 2019; **92**: e2444–54.
- Ekker MS, Boot EM, Singhal AB, et al. Epidemiology, aetiology, and management of ischaemic stroke in young adults. *Lancet Neurol* 2018; **17**: 790–801.
- O'Donnell MJ, Chin SL, Rangarajan S, et al. Global and regional effects of potentially modifiable risk factors associated with acute stroke in 32 countries (INTERSTROKE): a case-control study. *Lancet* 2016; **388**: 761–75.
- Verhoeven JI, Allach Y, Vaartjes ICH, Klijn CJM, de Leeuw FE. Ambient air pollution and the risk of ischaemic and haemorrhagic stroke. *Lancet Plan Health* 2021; **5**: e542–552.
- Adams HP Jr, Bendixen BH, Kappelle LJ, et al. Classification of subtype of acute ischemic stroke. Definitions for use in a multicenter clinical trial. TOAST. Trial of Org 10172 in Acute Stroke Treatment. *Stroke* 1993; **24**: 35–41.
- Dichgans M, Pulit SL, Rosand J. Stroke genetics: discovery, biology, and clinical applications. *Lancet Neurol* 2019; **18**: 587–99.
- Mishra A, Malik R, Hachiya T, et al. Stroke genetics informs drug discovery and risk prediction across ancestries. *Nature* 2022; **611**: 115–23.
- Traylor M, Persyn E, Tomppa L, et al. Genetic basis of lacunar stroke: a pooled analysis of individual patient data and genome-wide association studies. *Lancet Neurol* 2021; **20**: 351–61.
- Keep RF, Hua Y, Xi G. Intracerebral haemorrhage: mechanisms of injury and therapeutic targets. *Lancet Neurol* 2012; **11**: 720–31.
- Shao Z, Tu S, Shao A. Pathophysiological mechanisms and potential therapeutic targets in intracerebral hemorrhage. *Front Pharmacol* 2019; **10**: 1079.
- Morotti A, Boulouis G, Dowlatshahi D, et al. Intracerebral haemorrhage expansion: definitions, predictors, and prevention. *Lancet Neurol* 2023; **22**: 159–71.
- Wilkinson DA, Pandey AS, Thompson BG, Keep RF, Hua Y, Xi G. Injury mechanisms in acute intracerebral hemorrhage. *Neuropharmacology* 2018; **134**: 240–48.
- Chen Y, Chen S, Chang J, Wei J, Feng M, Wang R. Perihematomal edema after intracerebral hemorrhage: an update on pathogenesis, risk factors, and therapeutic advances. *Front Immunol* 2021; **12**: 740632.
- Cliteur MP, Sondag L, Cunningham L, et al. The association between perihematomal oedema and functional outcome after spontaneous intracerebral haemorrhage: a systematic review and meta-analysis. *Eur Stroke J* 2023; **8**: 423–33.
- Cordonnier C, Demchuk A, Ziai W, Anderson CS. Intracerebral haemorrhage: current approaches to acute management. *Lancet* 2018; **392**: 1257–68.
- Raposo N, Zanon Zotin MC, Seiffge DJ, et al. A causal classification system for intracerebral hemorrhage subtypes. *Ann Neurol* 2023; **93**: 16–28.
- Greenberg SM, Ziai WC, Cordonnier C, et al. 2022 guideline for the management of patients with spontaneous intracerebral hemorrhage: a guideline from the American Heart Association/American Stroke Association. *Stroke* 2022; **53**: e282–361.

- 26 Hilkens NA, van Asch CJ, Werring DJ, et al. Predicting the presence of macrovascular causes in non-traumatic intracerebral haemorrhage: the DIAGRAM prediction score. *J Neurol Neurosurg Psychiatry* 2018; **89**: 674–79.
- 27 van Asch CJ, Velthuis BK, Rinkel GJ, et al. Diagnostic yield and accuracy of CT angiography, MR angiography, and digital subtraction angiography for detection of macrovascular causes of intracerebral haemorrhage: prospective, multicentre cohort study. *BMJ* 2015; **351**: h5762.
- 28 Charidimou A, Boulouis G, Frosch MP, et al. The Boston criteria version 2.0 for cerebral amyloid angiopathy: a multicentre, retrospective, MRI-neuropathology diagnostic accuracy study. *Lancet Neurol* 2022; **21**: 714–25.
- 29 Rodrigues MA, Samarasekera N, Lerpiniere C, et al. The Edinburgh CT and genetic diagnostic criteria for lobar intracerebral haemorrhage associated with cerebral amyloid angiopathy: model development and diagnostic test accuracy study. *Lancet Neurol* 2018; **17**: 232–40.
- 30 Duering M, Biessels GJ, Brodtmann A, et al. Neuroimaging standards for research into small vessel disease-advances since 2013. *Lancet Neurol* 2023; **22**: 602–18.
- 31 Delgado Almandoz JE, Schaefer PW, Goldstein JN, et al. Practical scoring system for the identification of patients with intracerebral hemorrhage at highest risk of harboring an underlying vascular etiology: the secondary intracerebral hemorrhage score. *AJNR Am J Neuroradiol* 2010; **31**: 1653–60.
- 32 Delgado Almandoz JE, Jagadeesan BD, Moran CJ, et al. Independent validation of the secondary intracerebral hemorrhage score with catheter angiography and findings of emergent hematoma evacuation. *Neurosurgery* 2012; **70**: 131–40, discussion 140.
- 33 Saposnik G, Barinagarrementeria F, Brown RD Jr, et al. Diagnosis and management of cerebral venous thrombosis: a statement for healthcare professionals from the American Heart Association/American Stroke Association. *Stroke* 2011; **42**: 1158–92.
- 34 Aroor S, Singh R, Goldstein LB. BE-FAST (balance, eyes, face, arm, speech, time): reducing the proportion of strokes missed using the FAST mnemonic. *Stroke* 2017; **48**: 479–81.
- 35 Lima FO, Silva GS, Furie KL, et al. Field assessment stroke triage for emergency destination: a simple and accurate prehospital scale to detect large vessel occlusion strokes. *Stroke* 2016; **47**: 1997–2002.
- 36 Guterud M, Fagerheim Bugge H, Røislien J, et al. Prehospital screening of acute stroke with the National Institutes of Health Stroke Scale (Paranasal): a stepped-wedge, cluster-randomised controlled trial. *Lancet Neurol* 2023; **22**: 800–11.
- 37 Garcia-Tornel A, Millan M, Rubiera M, et al. Workflows and outcomes in patients with suspected large vessel occlusion stroke triaged in urban and nonurban areas. *Stroke* 2022; **53**: 3728–40.
- 38 Behrmdt A, Blauenfeldt RA, Johnsen SP, et al. Transport strategy in patients with suspected acute large vessel occlusion stroke: TRIAGE-STROKE, a randomized clinical trial. *Stroke* 2023; **54**: 2714–23.
- 39 Pérez de la Ossa N, Abilleira S, Jovin TG, et al. Effect of direct transportation to thrombectomy-capable center vs local stroke center on neurological outcomes in patients with suspected large-vessel occlusion stroke in nonurban areas: the RACECAT randomized clinical trial. *JAMA* 2022; **327**: 1782–94.
- 40 Turc G, Hadziahmetovic M, Walter S, et al. Comparison of mobile stroke unit with usual care for acute ischemic stroke management: a systematic review and meta-analysis. *JAMA Neurol* 2022; **79**: 281–90.
- 41 Berge E, Whiteley W, Audebert H, et al. European Stroke Organisation (ESO) guidelines on intravenous thrombolysis for acute ischaemic stroke. *Eur Stroke J* 2021; **6**: I–LXII.
- 42 Powers WJ, Rabinstein AA, Ackerson T, et al. Guidelines for the early management of patients with acute ischemic stroke: 2019 update to the 2018 guidelines for the early management of acute ischemic stroke: a guideline for healthcare professionals from the American Heart Association/American Stroke Association. *Stroke* 2019; **50**: e344–418.
- 43 The National Institute of Neurological Disorders and Stroke rt-PA Stroke Study Group. Tissue plasminogen activator for acute ischemic stroke. *N Engl J Med* 1995; **333**: 1581–87.
- 44 Hacke W, Kaste M, Bluhmki E, et al. Thrombolysis with alteplase 3 to 4.5 hours after acute ischemic stroke. *N Engl J Med* 2008; **359**: 1317–29.
- 45 Lansberg MG, Schrooten M, Bluhmki E, Thijs VN, Saver JL. Treatment time-specific number needed to treat estimates for tissue plasminogen activator therapy in acute stroke based on shifts over the entire range of the modified Rankin Scale. *Stroke* 2009; **40**: 2079–84.
- 46 Emberson J, Lees KR, Lyden P, et al. Effect of treatment delay, age, and stroke severity on the effects of intravenous thrombolysis with alteplase for acute ischaemic stroke: a meta-analysis of individual patient data from randomised trials. *Lancet* 2014; **384**: 1929–35.
- 47 Khatri P, Kleindorfer DO, Devlin T, et al. Effect of alteplase vs aspirin on functional outcome for patients with acute ischemic stroke and minor nondisabling neurologic deficits: the PRISMS randomized clinical trial. *JAMA* 2018; **320**: 156–66.
- 48 Chen HS, Cui Y, Zhou ZH, et al. Dual antiplatelet therapy vs alteplase for patients with minor nondisabling acute ischemic stroke: the ARAMIS randomized clinical trial. *JAMA* 2023; **329**: 2135–44.
- 49 Huang X, Cheripelli BK, Lloyd SM, et al. Alteplase versus tenecteplase for thrombolysis after ischaemic stroke (ATTEST): a phase 2, randomised, open-label, blinded endpoint study. *Lancet Neurol* 2015; **14**: 368–76.
- 50 Menon BK, Buck BH, Singh N, et al. Intravenous tenecteplase compared with alteplase for acute ischaemic stroke in Canada (ACT): a pragmatic, multicentre, open-label, registry-linked, randomised, controlled, non-inferiority trial. *Lancet* 2022; **400**: 161–69.
- 51 Kvistad CE, Næss H, Helleberg BH, et al. Tenecteplase versus alteplase for the management of acute ischaemic stroke in Norway (NOR-TEST 2, part A): a phase 3, randomised, open-label, blinded endpoint, non-inferiority trial. *Lancet Neurol* 2022; **21**: 511–19.
- 52 Wang Y, Li S, Pan Y, et al. Tenecteplase versus alteplase in acute ischaemic cerebrovascular events (TRACE-2): a phase 3, multicentre, open-label, randomised controlled, non-inferiority trial. *Lancet* 2023; **401**: 645–54.
- 53 Burgos AM, Saver JL. Evidence that tenecteplase is noninferior to alteplase for acute ischemic stroke: meta-analysis of 5 randomized trials. *Stroke* 2019; **50**: 2156–62.
- 54 Alamowitch S, Turc G, Palaodimou L, et al. European Stroke Organisation (ESO) expedited recommendation on tenecteplase for acute ischaemic stroke. *Eur Stroke J* 2023; **8**: 8–54.
- 55 Logallo N, Novotny V, Assmus J, et al. Tenecteplase versus alteplase for management of acute ischaemic stroke (NOR-TEST): a phase 3, randomised, open-label, blinded endpoint trial. *Lancet Neurol* 2017; **16**: 781–88.
- 56 Bivard A, Zhao H, Churilov L, et al. Comparison of tenecteplase with alteplase for the early treatment of ischaemic stroke in the Melbourne Mobile Stroke Unit (TASTE-A): a phase 2, randomised, open-label trial. *Lancet Neurol* 2022; **21**: 520–27.
- 57 Campbell BCV, Mitchell PJ, Churilov L, et al. Tenecteplase versus alteplase before thrombectomy for ischemic stroke. *N Engl J Med* 2018; **378**: 1573–82.
- 58 Campbell BCV, Mitchell PJ, Churilov L, et al. Effect of intravenous tenecteplase dose on cerebral reperfusion before thrombectomy in patients with large vessel occlusion ischemic stroke: the EXTEND-IA TNK part 2 randomized clinical trial. *JAMA* 2020; **323**: 1257–65.
- 59 Roaldsen MB, Eltoft A, Wilsaard T, et al. Safety and efficacy of tenecteplase in patients with wake-up stroke assessed by non-contrast CT (TWIST): a multicentre, open-label, randomised controlled trial. *Lancet Neurol* 2023; **22**: 117–26.
- 60 Campbell BCV, Ma H, Ringleb PA, et al. Extending thrombolysis to 4.5–9 h and wake-up stroke using perfusion imaging: a systematic review and meta-analysis of individual patient data. *Lancet* 2019; **394**: 139–47.
- 61 Ma H, Campbell BCV, Parsons MW, et al. Thrombolysis guided by perfusion imaging up to 9 hours after onset of stroke. *N Engl J Med* 2019; **380**: 1795–803.
- 62 Thomalla G, Simonsen CZ, Boutitie F, et al. MRI-guided thrombolysis for stroke with unknown time of onset. *N Engl J Med* 2018; **379**: 611–22.
- 63 Berkhemer OA, Fransen PS, Beumer D, et al. A randomized trial of intraarterial treatment for acute ischemic stroke. *N Engl J Med* 2015; **372**: 11–20.

- 64 Campbell BC, Mitchell PJ, Kleinig TJ, et al. Endovascular therapy for ischemic stroke with perfusion-imaging selection. *N Engl J Med* 2015; **372**: 1009–18.
- 65 Goyal M, Demchuk AM, Menon BK, et al. Randomized assessment of rapid endovascular treatment of ischemic stroke. *N Engl J Med* 2015; **372**: 1019–30.
- 66 Saver JL, Goyal M, Bonafe A, et al. Stent-retriever thrombectomy after intravenous t-PA vs t-PA alone in stroke. *N Engl J Med* 2015; **372**: 2285–95.
- 67 Jovin TG, Chamorro A, Cobo E, et al. Thrombectomy within 8 hours after symptom onset in ischemic stroke. *N Engl J Med* 2015; **372**: 2296–306.
- 68 Goyal M, Menon BK, van Zwam WH, et al. Endovascular thrombectomy after large-vessel ischaemic stroke: a meta-analysis of individual patient data from five randomised trials. *Lancet* 2016; **387**: 1723–31.
- 69 Nogueira RG, Jadhav AP, Haussen DC, et al. Thrombectomy 6 to 24 hours after stroke with a mismatch between deficit and infarct. *N Engl J Med* 2018; **378**: 11–21.
- 70 Albers GW, Marks MP, Kemp S, et al. Thrombectomy for stroke at 6 to 16 hours with selection by perfusion imaging. *N Engl J Med* 2018; **378**: 708–18.
- 71 Olthuis SGH, Pirson FAV, Pinckaers FME, et al. Endovascular treatment versus no endovascular treatment after 6–24 h in patients with ischaemic stroke and collateral flow on CT angiography (MR CLEAN-LATE) in the Netherlands: a multicentre, open-label, blinded-endpoint, randomised, controlled, phase 3 trial. *Lancet* 2023; **401**: 1371–80.
- 72 Jovin TG, Nogueira RG, Lansberg MG, et al. Thrombectomy for anterior circulation stroke beyond 6 h from time last known well (AURORA): a systematic review and individual patient data meta-analysis. *Lancet* 2022; **399**: 249–58.
- 73 Yoshimura S, Sakai N, Yamagami H, et al. Endovascular therapy for acute stroke with a large ischemic region. *N Engl J Med* 2022; **386**: 1303–13.
- 74 Sarraj A, Hassan AE, Abraham MG, et al. Trial of endovascular thrombectomy for large ischemic strokes. *N Engl J Med* 2023; **388**: 1259–71.
- 75 Huo X, Ma G, Tong X, et al. Trial of endovascular therapy for acute ischemic stroke with large infarct. *N Engl J Med* 2023; **388**: 1272–83.
- 76 Bendszus M, Fiehler J, Subtil F, et al. Endovascular thrombectomy for acute ischaemic stroke with established large infarct: multicentre, open-label, randomised trial. *Lancet* 2023; **402**: 1753–63.
- 77 Palaiodimos L, Sarraj A, Safouris A, et al. Endovascular treatment for large-core ischaemic stroke: a meta-analysis of randomised controlled clinical trials. *J Neurol Neurosurg Psychiatry* 2023; **94**: 781–85.
- 78 Tao C, Nogueira RG, Zhu Y, et al. Trial of endovascular treatment of acute basilar-artery occlusion. *N Engl J Med* 2022; **387**: 1361–72.
- 79 Jovin TG, Li C, Wu L, et al. Trial of thrombectomy 6 to 24 hours after stroke due to basilar-artery occlusion. *N Engl J Med* 2022; **387**: 1373–84.
- 80 Abdalkader M, Finitis S, Li C, et al. Endovascular versus medical management of acute basilar artery occlusion: a systematic review and meta-analysis of the randomized controlled trials. *J Stroke* 2023; **25**: 81–91.
- 81 Yang P, Zhang Y, Zhang L, et al. Endovascular thrombectomy with or without intravenous alteplase in acute stroke. *N Engl J Med* 2020; **382**: 1981–93.
- 82 Zi W, Qiu Z, Li F, et al. Effect of endovascular treatment alone vs intravenous alteplase plus endovascular treatment on functional independence in patients with acute ischemic stroke: the devt randomized clinical trial. *JAMA* 2021; **325**: 234–43.
- 83 Suzuki K, Matsumaru Y, Takeuchi M, et al. Effect of mechanical thrombectomy without vs with intravenous thrombolysis on functional outcome among patients with acute ischemic stroke: the SKIP randomized clinical trial. *JAMA* 2021; **325**: 244–53.
- 84 LeCouffe NE, Kappelhof M, Treurniet KM, et al. A randomized trial of intravenous alteplase before endovascular treatment for stroke. *N Engl J Med* 2021; **385**: 1833–44.
- 85 Mitchell PJ, Yan B, Churilov L, et al. Endovascular thrombectomy versus standard bridging thrombolytic with endovascular thrombectomy within 4–5 h of stroke onset: an open-label, blinded-endpoint, randomised non-inferiority trial. *Lancet* 2022; **400**: 116–25.
- 86 Turc G, Tsivgoulis G, Audebert HJ, et al. European Stroke Organisation—European Society for Minimally Invasive Neurological Therapy expedited recommendation on indication for intravenous thrombolysis before mechanical thrombectomy in patients with acute ischaemic stroke and anterior circulation large vessel occlusion. *Eur Stroke J* 2022; **7**: 1–XXVI.
- 87 Yang P, Song L, Zhang Y, et al. Intensive blood pressure control after endovascular thrombectomy for acute ischaemic stroke (ENCHANTED2/MT): a multicentre, open-label, blinded-endpoint, randomised controlled trial. *Lancet* 2022; **400**: 1585–96.
- 88 Nam HS, Kim YD, Heo J, et al. Intensive vs conventional blood pressure lowering after endovascular thrombectomy in acute ischemic stroke: the OPTIMAL-BP randomized clinical trial. *JAMA* 2023; **330**: 832–42.
- 89 Ma L, Hu X, Song L, et al. The third intensive care bundle with blood pressure reduction in acute cerebral haemorrhage trial (INTERACT3): an international, stepped wedge cluster randomised controlled trial. *Lancet* 2023; **402**: 27–40.
- 90 Li Q, Yakhkind A, Alexandrov AW, et al. Code ICH: a call to action. *Stroke* 2024; **55**: 494–505.
- 91 Parry-Jones AR, Sammut-Powell C, Paroutoglou K, et al. An intracerebral hemorrhage care bundle is associated with lower case fatality. *Ann Neurol* 2019; **86**: 495–503.
- 92 Gómez-Outes A, Alcubilla P, Calvo-Rojas G, et al. Meta-analysis of reversal agents for severe bleeding associated with direct oral anticoagulants. *J Am Coll Cardiol* 2021; **77**: 2987–3001.
- 93 Steiner T, Poli S, Griebel M, et al. Fresh frozen plasma versus prothrombin complex concentrate in patients with intracranial haemorrhage related to vitamin K antagonists (INCH): a randomised trial. *Lancet Neurol* 2016; **15**: 566–73.
- 94 Connolly SJ, Crowther M, Eikelboom JW, et al. Full study report of andexanet alfa for bleeding associated with factor Xa inhibitors. *N Engl J Med* 2019; **380**: 1326–35.
- 95 Demchuk AM, Yue P, Zotova E, et al. Hemostatic efficacy and anti-FXa (factor Xa) reversal with andexanet alfa in intracranial hemorrhage: ANNEXA-4 substudy. *Stroke* 2021; **52**: 2096–105.
- 96 Chuck CC, Kim D, Kalagara R, et al. Modeling the clinical implications of andexanet alfa in factor xa inhibitor-associated intracerebral hemorrhage. *Neurology* 2021; **97**: e2054–64.
- 97 Panos NG, Cook AM, John S, et al. Factor Xa inhibitor-related intracranial hemorrhage: results from a multicenter, observational cohort receiving prothrombin complex concentrates. *Circulation* 2020; **141**: 1681–89.
- 98 Giovino A, Shomo E, Busey KV, Case D, Brockhurst A, Concha M. An 18-month single-center observational study of real-world use of andexanet alfa in patients with factor Xa inhibitor associated intracranial hemorrhage. *Clin Neurol Neurosurg* 2020; **195**: 106070.
- 99 Barra ME, Das AS, Hayes BD, et al. Evaluation of andexanet alfa and four-factor prothrombin complex concentrate (4F-PCC) for reversal of rivaroxaban- and apixaban-associated intracranial hemorrhages. *J Thromb Haemost* 2020; **18**: 1637–47.
- 100 Pollack CV Jr, Reilly PA, van Ryn J, et al. Idarucizumab for dabigatran reversal—full cohort analysis. *N Engl J Med* 2017; **377**: 431–41.
- 101 Castillo R, Chan A, Atallah S, et al. Treatment of adults with intracranial hemorrhage on apixaban or rivaroxaban with prothrombin complex concentrate products. *J Thromb Thrombolysis* 2021; **51**: 151–58.
- 102 Piran S, Khatib R, Schulman S, et al. Management of direct factor Xa inhibitor-related major bleeding with prothrombin complex concentrate: a meta-analysis. *Blood Adv* 2019; **3**: 158–67.
- 103 Baharoglu MI, Cordonnier C, Al-Shahi Salman R, et al. Platelet transfusion versus standard care after acute stroke due to spontaneous cerebral haemorrhage associated with antiplatelet therapy (PATCH): a randomised, open-label, phase 3 trial. *Lancet* 2016; **387**: 2605–13.
- 104 Gladstone DJ, Aviv RI, Demchuk AM, et al. Effect of recombinant activated coagulation factor VII on hemorrhage expansion among patients with spot sign-positive acute intracerebral hemorrhage: the SPOTLIGHT and STOP-IT randomized clinical trials. *JAMA Neurol* 2019; **76**: 1493–501.
- 105 Nie X, Liu J, Liu D, et al. Haemostatic therapy in spontaneous intracerebral haemorrhage patients with high-risk of haematoma expansion by CT marker: a systematic review and meta-analysis of randomised trials. *Stroke Vasc Neurol* 2021; **6**: 170–79.

- 106 Law ZK, Desborough M, Roberts I, et al. Outcomes in antiplatelet-associated intracerebral hemorrhage in the TICH-2 randomized controlled trial. *J Am Heart Assoc* 2021; **10**: e019130.
- 107 Liu J, Nie X, Gu H, et al. Tranexamic acid for acute intracerebral haemorrhage growth based on imaging assessment (TRAIGE): a multicentre, randomised, placebo-controlled trial. *Stroke Vasc Neurol* 2021; **6**: 160–69.
- 108 Meretoja A, Yassi N, Wu TY, et al. Tranexamic acid in patients with intracerebral haemorrhage (STOP-AUST): a multicentre, randomised, placebo-controlled, phase 2 trial. *Lancet Neurol* 2020; **19**: 980–87.
- 109 Sprigg N, Flaherty K, Appleton JP, et al. Tranexamic acid for hyperacute primary intracerebral haemorrhage (TICH-2): an international randomised, placebo-controlled, phase 3 superiority trial. *Lancet* 2018; **391**: 2107–15.
- 110 Polymeris AA, Karwacki GM, Siepen BM, et al. Tranexamic acid for intracerebral hemorrhage in patients on non-vitamin k antagonist oral anticoagulants (TICH-NOAC): a multicenter, randomized, placebo-controlled, phase 2 trial. *Stroke* 2023; **54**: 2223–34.
- 111 Yogendrakumar V, Wu TY, Churilov L, et al. Does tranexamic acid affect intraventricular hemorrhage growth in acute ICH? An analysis of the STOP-AUST trial. *Eur Stroke J* 2022; **7**: 15–19.
- 112 Li Q, Warren AD, Qureshi AI, et al. Ultra-early blood pressure reduction attenuates hematoma growth and improves outcome in intracerebral hemorrhage. *Ann Neurol* 2020; **88**: 388–95.
- 113 Qureshi AI, Palesch YY, Barsan WG, et al. Intensive blood-pressure lowering in patients with acute cerebral hemorrhage. *N Engl J Med* 2016; **375**: 1033–43.
- 114 Arima H, Heeley E, Delcourt C, et al. Optimal achieved blood pressure in acute intracerebral hemorrhage: INTERACT2. *Neurology* 2015; **84**: 464–71.
- 115 Bath PM, Woodhouse LJ, Krishnan K, et al. Prehospital transdermal glyceryl trinitrate for ultra-acute intracerebral hemorrhage: data from the RIGHT-2 trial. *Stroke* 2019; **50**: 3064–71.
- 116 Anderson CS, Heeley E, Huang Y, et al. Rapid blood-pressure lowering in patients with acute intracerebral hemorrhage. *N Engl J Med* 2013; **368**: 2355–65.
- 117 Moullaali TJ, Wang X, Martin RH, et al. Blood pressure control and clinical outcomes in acute intracerebral haemorrhage: a preplanned pooled analysis of individual participant data. *Lancet Neurol* 2019; **18**: 857–64.
- 118 Boulouis G, Morotti A, Goldstein JN, Charidimou A. Intensive blood pressure lowering in patients with acute intracerebral haemorrhage: clinical outcomes and haemorrhage expansion. Systematic review and meta-analysis of randomised trials. *J Neurol Neurosurg Psychiatry* 2017; **88**: 339–45.
- 119 Gong S, Lin C, Zhang D, et al. Effects of intensive blood pressure reduction on acute intracerebral hemorrhage: a systematic review and meta-analysis. *Sci Rep* 2017; **7**: 10694.
- 120 Lattanzi S, Cagnetti C, Provinciali L, Silvestrini M. How should we lower blood pressure after cerebral hemorrhage? A systematic review and meta-analysis. *Cerebrovasc Dis* 2017; **43**: 207–13.
- 121 Wang X, Arima H, Al-Shahi Salman R, et al. Rapid blood pressure lowering according to recovery at different time intervals after acute intracerebral hemorrhage: pooled analysis of the INTERACT studies. *Cerebrovasc Dis* 2015; **39**: 242–48.
- 122 Manning L, Hirakawa Y, Arima H, et al. Blood pressure variability and outcome after acute intracerebral haemorrhage: a post-hoc analysis of INTERACT2, a randomised controlled trial. *Lancet Neurol* 2014; **13**: 364–73.
- 123 Moullaali TJ, Wang X, Sandset EC, et al. Early lowering of blood pressure after acute intracerebral haemorrhage: a systematic review and meta-analysis of individual patient data. *J Neurol Neurosurg Psychiatry* 2022; **93**: 6–13.
- 124 Scaggiante J, Zhang X, Mocco J, Kellner CP. Minimally invasive surgery for intracerebral hemorrhage. *Stroke* 2018; **49**: 2612–20.
- 125 Sondag L, Schreuder FHB, Boogaarts HD, et al. Neurosurgical intervention for supratentorial intracerebral hemorrhage. *Ann Neurol* 2020; **88**: 239–50.
- 126 Hanley DF, Lane K, McBee N, et al. Thrombolytic removal of intraventricular haemorrhage in treatment of severe stroke: results of the randomised, multicentre, multiregion, placebo-controlled CLEAR III trial. *Lancet* 2017; **389**: 603–11.
- 127 Hanley DF, Thompson RE, Muschelli J, et al. Safety and efficacy of minimally invasive surgery plus alteplase in intracerebral haemorrhage evacuation (MISTIE): a randomised, controlled, open-label, phase 2 trial. *Lancet Neurol* 2016; **15**: 1228–37.
- 128 Hanley DF, Thompson RE, Rosenblum M, et al. Efficacy and safety of minimally invasive surgery with thrombolysis in intracerebral haemorrhage evacuation (MISTIE III): a randomised, controlled, open-label, blinded endpoint phase 3 trial. *Lancet* 2019; **393**: 1021–32.
- 129 Mendelow AD, Gregson BA, Rowan EN, Murray GD, Ghohar A, Mitchell PM. Early surgery versus initial conservative treatment in patients with spontaneous supratentorial lobar intracerebral haematomas (STICH II): a randomised trial. *Lancet* 2013; **382**: 397–408.
- 130 Guo G, Pan C, Guo W, et al. Efficacy and safety of four interventions for spontaneous supratentorial intracerebral hemorrhage: a network meta-analysis. *J Neurointerv Surg* 2020; **12**: 598–604.
- 131 Li M, Mu F, Su D, Han Q, Guo Z, Chen T. Different surgical interventions for patients with spontaneous supratentorial intracranial hemorrhage: a network meta-analysis. *Clin Neurol Neurosurg* 2020; **188**: 105617.
- 132 Tang Y, Yin F, Fu D, Gao X, Lv Z, Li X. Efficacy and safety of minimal invasive surgery treatment in hypertensive intracerebral hemorrhage: a systematic review and meta-analysis. *BMC Neurol* 2018; **18**: 136.
- 133 Zhou X, Chen J, Li Q, et al. Minimally invasive surgery for spontaneous supratentorial intracerebral hemorrhage: a meta-analysis of randomized controlled trials. *Stroke* 2012; **43**: 2923–30.
- 134 Zhou X, Xie L, Altinel Y, Qiao N. Assessment of evidence regarding minimally invasive surgery vs. conservative treatment on intracerebral hemorrhage: a trial sequential analysis of randomized controlled trials. *Front Neurol* 2020; **11**: 426.
- 135 Sun S, Li Y, Zhang H, et al. Neuroendoscopic Surgery versus craniotomy for supratentorial hypertensive intracerebral hemorrhage: a systematic review and meta-analysis. *World Neurosurg* 2020; **134**: 477–88.
- 136 Akhigbe T, Okafor U, Sattar T, Rawluk D, Fahey T. Stereotactic-guided evacuation of spontaneous supratentorial intracerebral hemorrhage: systematic review and meta-analysis. *World Neurosurg* 2015; **84**: 451–60.
- 137 Mould WA, Carhuapoma JR, Muschelli J, et al. Minimally invasive surgery plus recombinant tissue-type plasminogen activator for intracerebral hemorrhage evacuation decreases perihematomal edema. *Stroke* 2013; **44**: 627–34.
- 138 Langhorne P, Ramachandra S. Organised inpatient (stroke unit) care for stroke: network meta-analysis. *Cochrane Database Syst Rev* 2020; **4**: CD000197.
- 139 Middleton S, McElduff P, Ward J, et al. Implementation of evidence-based treatment protocols to manage fever, hyperglycaemia, and swallowing dysfunction in acute stroke (QASC): a cluster randomised controlled trial. *Lancet* 2011; **378**: 1699–706.
- 140 Reinink H, Jüttler E, Hacke W, et al. Surgical decompression for space-occupying hemispheric infarction: a systematic review and individual patient meta-analysis of randomized clinical trials. *JAMA Neurol* 2021; **78**: 208–16.
- 141 Balami JS, Chen RL, Grunwald IQ, Buchan AM. Neurological complications of acute ischaemic stroke. *Lancet Neurol* 2011; **10**: 357–71.
- 142 Rothwell PM, Giles MF, Chandratheva A, et al. Effect of urgent treatment of transient ischaemic attack and minor stroke on early recurrent stroke (EXPRESS study): a prospective population-based sequential comparison. *Lancet* 2007; **370**: 1432–42.
- 143 Wang Y, Wang Y, Zhao X, et al. Clopidogrel with aspirin in acute minor stroke or transient ischemic attack. *N Engl J Med* 2013; **369**: 11–19.
- 144 Johnston SC, Easton JD, Farrant M, et al. Clopidogrel and aspirin in acute ischemic stroke and high-risk TIA. *N Engl J Med* 2018; **379**: 215–25.
- 145 Pan Y, Meng X, Jin A, et al. Time course for benefit and risk with ticagrelor and aspirin in individuals with acute ischemic stroke or transient ischemic attack who carry cyp2c19 loss-of-function alleles: a secondary analysis of the CHANCE-2 randomized clinical trial. *JAMA Neurol* 2022; **79**: 739–45.
- 146 Gao Y, Chen W, Pan Y, et al. Dual antiplatelet treatment up to 72 hours after ischemic stroke. *N Engl J Med* 2023; **389**: 2413–24.

- 147 Johnston SC, Amarenco P, Denison H, et al. Ticagrelor and aspirin or aspirin alone in acute ischemic stroke or TIA. *N Engl J Med* 2020; **383**: 207–17.
- 148 Pan Y, Chen W, Xu Y, et al. Genetic polymorphisms and clopidogrel efficacy for acute ischemic stroke or transient ischemic attack: a systematic review and meta-analysis. *Circulation* 2017; **135**: 21–33.
- 149 Wang Y, Zhao X, Lin J, et al. Association between cyp2c19 loss-of-function allele status and efficacy of clopidogrel for risk reduction among patients with minor stroke or transient ischemic attack. *JAMA* 2016; **316**: 70–78.
- 150 Wang Y, Meng X, Wang A, et al. Ticagrelor versus clopidogrel in CYP2C19 loss-of-function carriers with stroke or TIA. *N Engl J Med* 2021; **385**: 2520–30.
- 151 Meng X, Wang A, Tian X, et al. One-year outcomes of early therapy with ticagrelor vs clopidogrel in CYP2C19 loss-of-function carriers with stroke or TIA trial. *Neurology* 2024; **102**: e207809.
- 152 Toyoda K, Uchiyama S, Yamaguchi T, et al. Dual antiplatelet therapy using cilostazol for secondary prevention in patients with high-risk ischaemic stroke in Japan: a multicentre, open-label, randomised controlled trial. *Lancet Neurol* 2019; **18**: 539–48.
- 153 Wardlaw JM, Woodhouse LJ, Mhlanga II, et al. Isosorbide mononitrate and cilostazol treatment in patients with symptomatic cerebral small vessel disease: the lacunar intervention trial-2 (LACI-2) randomized clinical trial. *JAMA Neurol* 2023; **80**: 682–92.
- 154 Diener HC, Sacco RL, Easton JD, et al. Dabigatran for prevention of stroke after embolic stroke of undetermined source. *N Engl J Med* 2019; **380**: 1906–17.
- 155 Hart RG, Sharma M, Mundl H, et al. Rivaroxaban for stroke prevention after embolic stroke of undetermined source. *N Engl J Med* 2018; **378**: 2191–201.
- 156 Ruff CT, Giugliano RP, Braunwald E, et al. Comparison of the efficacy and safety of new oral anticoagulants with warfarin in patients with atrial fibrillation: a meta-analysis of randomised trials. *Lancet* 2014; **383**: 955–62.
- 157 Fischer U, Koga M, Strbian D, et al. Early versus later anticoagulation for stroke with atrial fibrillation. *N Engl J Med* 2023; **388**: 2411–21.
- 158 Oldgren J, Åsberg S, Hijazi Z, Wester P, Bertilsson M, Norrving B. early versus delayed non-vitamin K antagonist oral anticoagulant therapy after acute ischemic stroke in atrial fibrillation (TIMING): a registry-based randomized controlled noninferiority study. *Circulation* 2022; **146**: 1056–66.
- 159 Zonneveld TP, Richard E, Vergouwen MD, et al. Blood pressure-lowering treatment for preventing recurrent stroke, major vascular events, and dementia in patients with a history of stroke or transient ischaemic attack. *Cochrane Database Syst Rev* 2018; **7**: CD007858.
- 160 Hsu CY, Saver JL, Ovbiagele B, Wu YL, Cheng CY, Lee M. Association Between magnitude of differential blood pressure reduction and secondary stroke prevention: a meta-analysis and meta-regression. *JAMA Neurol* 2023; **80**: 506–15.
- 161 Kitagawa K, Yamamoto Y, Arima H, et al. Effect of standard vs intensive blood pressure control on the risk of recurrent stroke: a randomized clinical trial and meta-analysis. *JAMA Neurol* 2019; **76**: 1309–18.
- 162 Lakhan SE, Sapko MT. Blood pressure lowering treatment for preventing stroke recurrence: a systematic review and meta-analysis. *Int Arch Med* 2009; **2**: 30.
- 163 Liu L, Xie X, Pan Y, et al. Early versus delayed antihypertensive treatment in patients with acute ischaemic stroke: multicentre, open label, randomised, controlled trial. *BMJ* 2023; **383**: e076448.
- 164 Amarenco P, Kim JS, Labreuche J, et al. A comparison of two LDL cholesterol targets after ischemic stroke. *N Engl J Med* 2020; **382**: 9–19.
- 165 No authors listed. Intensive blood-glucose control with sulphonylureas or insulin compared with conventional treatment and risk of complications in patients with type 2 diabetes (UKPDS 33). UK Prospective Diabetes Study (UKPDS) Group. *Lancet* 1998; **352**: 837–53.
- 166 Gerstein HC, Miller ME, Byington RP, et al. Effects of intensive glucose lowering in type 2 diabetes. *N Engl J Med* 2008; **358**: 2545–59.
- 167 Patel A, MacMahon S, Chalmers J, et al. Intensive blood glucose control and vascular outcomes in patients with type 2 diabetes. *N Engl J Med* 2008; **358**: 2560–72.
- 168 Duckworth W, Abraira C, Moritz T, et al. Glucose control and vascular complications in veterans with type 2 diabetes. *N Engl J Med* 2009; **360**: 129–39.
- 169 Banerjee M, Pal R, Mukhopadhyay S, Nair K. GLP-1 receptor agonists and risk of adverse cerebrovascular outcomes in type 2 diabetes: a systematic review and meta-analysis of randomized controlled trials. *J Clin Endocrinol Metab* 2023; **108**: 1806–12.
- 170 Schwarzbach CJ, Eichner FA, Rücker V, et al. The structured ambulatory post-stroke care program for outpatient aftercare in patients with ischaemic stroke in Germany (SANO): an open-label, cluster-randomised controlled trial. *Lancet Neurol* 2023; **22**: 787–99.
- 171 Ahmadi M, Laumeier I, Ihl T, et al. A support programme for secondary prevention in patients with transient ischaemic attack and minor stroke (INSPIRE-TMS): an open-label, randomised controlled trial. *Lancet Neurol* 2020; **19**: 49–60.
- 172 Feng X, Chan KL, Lan L, et al. Stroke mechanisms in symptomatic intracranial atherosclerotic disease: classification and clinical implications. *Stroke* 2019; **50**: 2692–99.
- 173 Chaturvedi S, Turan TN, Lynn MJ, et al. Do patient characteristics explain the differences in outcome between medically treated patients in SAMMPRIS and WASID? *Stroke* 2015; **46**: 2562–67.
- 174 Luo J, Wang T, Yang K, et al. Endovascular therapy versus medical treatment for symptomatic intracranial artery stenosis. *Cochrane Database Syst Rev* 2023; **2**: CD013267.
- 175 Gao P, Wang T, Wang D, et al. Effect of stenting plus medical therapy vs medical therapy alone on risk of stroke and death in patients with symptomatic intracranial stenosis: the CASSISS randomized clinical trial. *JAMA* 2022; **328**: 534–42.
- 176 Hou C, Lan J, Lin Y, et al. Chronic remote ischaemic conditioning in patients with symptomatic intracranial atherosclerotic stenosis (the RICA trial): a multicentre, randomised, double-blind sham-controlled trial in China. *Lancet Neurol* 2022; **21**: 1089–98.
- 177 Merkler AE, Gialdini G, Yaghi S, et al. Safety outcomes after percutaneous transcatheter closure of patent foramen ovale. *Stroke* 2017; **48**: 3073–77.
- 178 Kent DM, Saver JL, Kasner SE, et al. Heterogeneity of treatment effects in an analysis of pooled individual patient data from randomized trials of device closure of patent foramen ovale after stroke. *JAMA* 2021; **326**: 2277–86.
- 179 Charidimou A, Imaizumi T, Moulin S, et al. Brain hemorrhage recurrence, small vessel disease type, and cerebral microbleeds: A meta-analysis. *Neurology* 2017; **89**: 820–29.
- 180 Charidimou A, Boulouis G, Roongpiboonsopit D, et al. Cortical superficial siderosis and recurrent intracerebral hemorrhage risk in cerebral amyloid angiopathy: large prospective cohort and preliminary meta-analysis. *Int J Stroke* 2019; **14**: 723–33.
- 181 Chen Y, Wright N, Guo Y, et al. Mortality and recurrent vascular events after first incident stroke: a 9-year community-based study of 0.5 million Chinese adults. *Lancet Glob Health* 2020; **8**: e580–90.
- 182 van Nieuwenhuizen KM, Vaartjes I, Verhoeven JJ, et al. Long-term prognosis after intracerebral haemorrhage. *Eur Stroke J* 2020; **5**: 336–44.
- 183 Murthy SB, Diaz I, Wu X, et al. Risk of arterial ischemic events after intracerebral hemorrhage. *Stroke* 2020; **51**: 137–42.
- 184 Murthy SB, Zhang C, Diaz I, et al. Association between intracerebral hemorrhage and subsequent arterial ischemic events in participants from 4 population-based cohort studies. *JAMA Neurol* 2021; **78**: 809–16.
- 185 Collaboration R. Effects of antiplatelet therapy after stroke due to intracerebral haemorrhage (RESTART): a randomised, open-label trial. *Lancet* 2019; **393**: 2613–23.
- 186 Al-Shahi Salman R, Minks DP, Mitra D, et al. Effects of antiplatelet therapy on stroke risk by brain imaging features of intracerebral haemorrhage and cerebral small vessel diseases: subgroup analyses of the RESTART randomised, open-label trial. *Lancet Neurol* 2019; **18**: 643–52.
- 187 Al-Shahi Salman R, Dennis MS, Sandercock PAG, et al. Effects of antiplatelet therapy after stroke caused by intracerebral hemorrhage: extended follow-up of the RESTART randomized clinical trial. *JAMA Neurol* 2021; **78**: 1179–86.

- 188 Liu C-H, Wu Y-L, Hsu C-C, Lee T-H. Early antiplatelet resumption and the risks of major bleeding after intracerebral hemorrhage. *Stroke* 2023; **54**: 537–45.
- 189 Li L, Poon MTC, Samarasekera NE, et al. Risks of recurrent stroke and all serious vascular events after spontaneous intracerebral haemorrhage: pooled analyses of two population-based studies. *Lancet Neurol* 2021; **20**: 437–47.
- 190 Korompoki E, Filippidis FT, Nielsen PB, et al. Long-term antithrombotic treatment in intracranial hemorrhage survivors with atrial fibrillation. *Neurology* 2017; **89**: 687–96.
- 191 Biffi A, Kuramatsu JB, Leasure A, et al. Oral anticoagulation and functional outcome after intracerebral hemorrhage. *Ann Neurol* 2017; **82**: 755–65.
- 192 Pennlert J, Overholser R, Asplund K, et al. Optimal timing of anticoagulant treatment after intracerebral hemorrhage in patients with atrial fibrillation. *Stroke* 2017; **48**: 314–20.
- 193 Kuramatsu JB, Huttner HB. Management of oral anticoagulation after intracerebral hemorrhage. *Int J Stroke* 2019; **14**: 238–46.
- 194 Schreuder FHBM, van Nieuwenhuizen KM, Hofmeijer J, et al. Apixaban versus no anticoagulation after anticoagulation-associated intracerebral hemorrhage in patients with atrial fibrillation in the Netherlands (APACHE-AF): a randomised, open-label, phase 2 trial. *Lancet Neurol* 2021; **20**: 907–16.
- 195 So SC. Effects of oral anticoagulation for atrial fibrillation after spontaneous intracranial haemorrhage in the UK: a randomised, open-label, assessor-masked, pilot-phase, non-inferiority trial. *Lancet Neurol* 2021; **20**: 842–53.
- 196 Turagam MK, Osmancik P, Neuzil P, Dukkupati SR, Reddy VY. Left atrial appendage closure versus oral anticoagulants in atrial fibrillation: a meta-analysis of randomized trials. *J Am Coll Cardiol* 2020; **76**: 2795–97.
- 197 Kuramatsu JB, Sembill JA, Gerner ST, et al. Management of therapeutic anticoagulation in patients with intracerebral haemorrhage and mechanical heart valves. *Eur Heart J* 2018; **39**: 1709–23.
- 198 Lun R, Yogendrakumar V, Ramsay T, et al. Predicting long-term outcomes in acute intracerebral haemorrhage using delayed prognostication scores. *Stroke Vasc Neurol* 2021; **6**: 536–41.
- 199 Hankey GJ, Hackett ML, Almeida OP, et al. Safety and efficacy of fluoxetine on functional outcome after acute stroke (AFFINITY): a randomised, double-blind, placebo-controlled trial. *Lancet Neurol* 2020; **19**: 651–60.
- 200 Lundström E, Isaksson E, Näsman P, et al. Safety and efficacy of fluoxetine on functional recovery after acute stroke (EFFECTS): a randomised, double-blind, placebo-controlled trial. *Lancet Neurol* 2020; **19**: 661–69.
- 201 Dennis M, Mead G, Forbes J, et al. Effects of fluoxetine on functional outcomes after acute stroke (FOCUS): a pragmatic, double-blind, randomised, controlled trial. *Lancet* 2019; **393**: 265–74.
- 202 Mehrholz J, Pohl M, Platz T, Kugler J, Elsner B. Electromechanical and robot-assisted arm training for improving activities of daily living, arm function, and arm muscle strength after stroke. *Cochrane Database Syst Rev* 2018; **9**: CD006876.
- 203 Rodgers H, Bosomworth H, Krebs HI, et al. Robot assisted training for the upper limb after stroke (RATULS): a multicentre randomised controlled trial. *Lancet* 2019; **394**: 51–62.
- 204 Dawson J, Liu CY, Francisco GE, et al. Vagus nerve stimulation paired with rehabilitation for upper limb motor function after ischaemic stroke (VNS-REHAB): a randomised, blinded, pivotal, device trial. *Lancet* 2021; **397**: 1545–53.
- 205 Palmer R, Dimairo M, Cooper C, et al. Self-managed, computerised speech and language therapy for patients with chronic aphasia post-stroke compared with usual care or attention control (big CACTUS): a multicentre, single-blinded, randomised controlled trial. *Lancet Neurol* 2019; **18**: 821–33.
- 206 WHO. Package of interventions for rehabilitation. <https://www.who.int/activities/integrating-rehabilitation-into-health-systems/service-delivery/package-of-interventions-for-rehabilitation> (accessed March 14, 2024).
- 207 Pollock A, St George B, Fenton M, Firkins L. Top 10 research priorities relating to life after stroke—consensus from stroke survivors, caregivers, and health professionals. *Int J Stroke* 2014; **9**: 313–20.
- 208 Feigin VL, Owolabi MO, Feigin VL, et al. Pragmatic solutions to reduce the global burden of stroke: a World Stroke Organization–Lancet Neurology Commission. *Lancet Neurol* 2023; **22**: 1160–206.

Copyright © 2024 Elsevier Ltd. All rights reserved, including those for text and data mining, AI training, and similar technologies.